

# The value of staging laparoscopy in gastric cancer

Nikolaos Machairas<sup>a</sup>, Petros Charalampoudis<sup>a</sup>, Ernesto P. Molmenti<sup>b</sup>, Stylianos Kykalos<sup>a</sup>, Peter Tsaparas<sup>a</sup>, Paraskevas Stamopoulos<sup>a</sup>, Georgios C. Sotiropoulos<sup>a</sup>

National and Kapodistrian University of Athens, Medical School, Laiko General Hospital, Athens, Greece; North Shore University Hospital, Manhasset, New York, USA

## Abstract

Treatment options for patients with gastric cancer (GC) are based on tumor staging and resectability. Although only surgery provides improved survival, resection is contraindicated and should be avoided in the presence of intra-abdominal disease stage M1 (liver, peritoneal, or non-local lymph node metastases). Thus, a detailed and precise evaluation is imperative for optimal treatment. Staging laparoscopy (SL) constitutes a major tool in the accurate diagnosis of several types of cancers, including GC. SL presents several critical advantages: it can diagnose intra-abdominal disease; serve as a complement to other imaging studies; allow for biopsies; facilitate intraoperative ultrasound evaluations; allow for sampling of peritoneal fluid for cytological examination; and serve as an option for the administration of intraperitoneal chemotherapy. Although considered and advocated as a very useful asset in the pre-treatment cancer-staging arsenal, the wider application of SL has been long debated. The purpose of our study was to evaluate the contribution of laparoscopy to GC staging.

**Keywords** Gastric cancer, staging, laparoscopy

*Ann Gastroenterol* 2017; 30 (3): 1-8

## Introduction

Staging laparoscopy (SL) plays a cardinal role in the investigation algorithm of patients with gastric cancer (GC) and helps provide the optimal treatment (Fig. 1). Although several studies have documented its critical benefits for the patients, it has not yet been established as a standard procedure. The role of laparoscopy in the staging of GC was introduced in the early 1980s. A retrospective analysis of 193 cases by Popova *et al* showed that surgery for GC could have been avoided in 42.5% of instances if laparoscopy had been instituted during the initial evaluation [1]. Other studies from

that time period demonstrated both the safety of laparoscopy when performed by experienced surgeons and the significant morbidity and mortality of unnecessary laparotomies for upper gastrointestinal cancers. Laparoscopic examination of the peritoneal cavity provides additional unique possibilities, such as sampling of ascitic fluid for cytological evaluation, concomitant use of laparoscopic ultrasound (LUS) to exclude small liver metastases, detection of tumoral invasion of the diaphragm, and evaluation of abdominal lymph nodes for malignant involvement [2].

The purpose of the present study was to evaluate laparoscopy by comparing it to other diagnostic modalities such as computed tomography (CT), positron emission tomography (PET)/CT, and endoscopic ultrasound (EUS) in the staging of GC. The role of minimally invasive LUS, peritoneal cytology, and administration of intraperitoneal chemotherapy is also discussed.

## Technique of SL

The patient is placed in the supine position and pneumoperitoneum is established. Ascitic fluid, if found, is collected for cytology. SL begins with inspection of the peritoneal cavity. If no metastatic disease is identified, the left lateral lobe of the liver is elevated to expose the entire stomach. The gastric tumor is inspected for invasion beyond the serosal layer and infiltration into adjacent structures. In instances of posterior

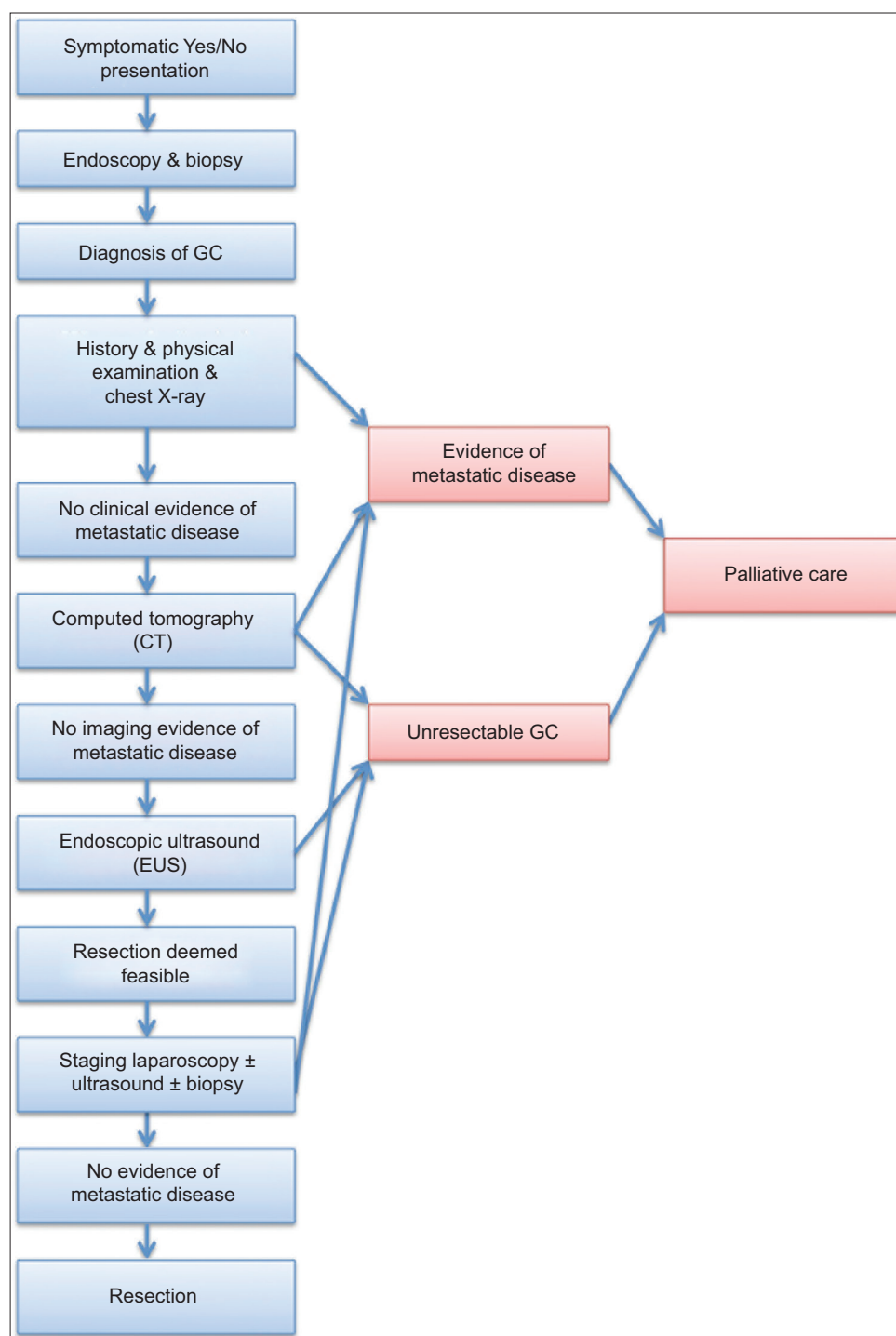
<sup>a</sup>2<sup>nd</sup> Department of Propaedeutic Surgery, National and Kapodistrian University of Athens, Medical School, Laiko General Hospital, Athens, Greece (Nikolaos Machairas, Petros Charalampoudis, Stylianos Kykalos, Peter Tsaparas, Paraskevas Stamopoulos, Georgios C. Sotiropoulos); <sup>b</sup>Department of Surgery, North Shore University Hospital, Manhasset, New York, USA (Ernesto P. Molmenti)

Conflict of Interest: None

Correspondence to: Dr. Georgios C. Sotiropoulos, PhD, FACS, FEBS, 2<sup>nd</sup> Department of Propaedeutic Surgery, Laiko General Hospital, Ag. Thoma 17, Athens 11527, Greece, Tel.: +30 210 7456372, Fax: +30 210 7709949, e-mail: georgios.sotiropoulos@uni-due.de

Received 27 November 2016; accepted 19 February 2017; published online 16 March 2017

DOI: <https://doi.org/10.20524/aog.2017.0133>



**Figure 1** Investigation algorithm for patients with gastric cancer (GC)

lesions, the lesser sac is accessed to visualize the tumor [2,3]. The hepatogastric ligament and the porta hepatis are also inspected [3]. Peritoneal lavage, LUS, and administration of intraperitoneal chemotherapy are available options. In cases of suspected lymph node positivity upgrading the stage to level IV disease, additional provisional biopsies can be performed. Nevertheless, since such nodes are located outside tier 2

(i.e. para-aortic, retropancreatic), it must be highlighted that access to these anatomic locations is considered laborious, even with non-minimal approach techniques. Dissecting the path to these locations might prove a challenging and risky task to undertake and may modify the diagnostic character of the procedure into “operative”. Moreover, these procedures require advanced laparoscopic skills.

## Indications for SL

In 2009, an expert panel of physicians thoroughly evaluated the indications, contraindications, risks, benefits, diagnostic accuracy, associated morbidity, limitations, and evidence-based recommendations of SL in the setting of GC and concluded that pretreatment TNM stage determination was indispensable, and that laparoscopy should be performed prior to cT3-cT4 (c for “clinical” staging), or when multi-visceral resections are planned in cases of locally advanced tumors probably invading adjacent structures [4].

Grundmann *et al* showed that laparoscopy was effective for staging T3 and T4 tumors, avoiding unnecessary laparotomies, and improving the detection of small liver and peritoneal metastases [5]. A study from the University Hospital of Essen [6] showed that laparoscopy modified the TNM classification in 46 of 125 cases of esophagogastric tumor cases, upstaging N and M (n=15 and 28, respectively) and downstaging T (n=3). A large study of patients aged 65 and older found that SL was considered only infrequently in the management of gastric adenocarcinoma, and that its implementation could have substantially reduced the morbidity and mortality of non-therapeutic laparotomies [7]. It was also observed that hand-assisted laparoscopic staging enabled the assessment accuracy of tumor resectability in locally advanced tumors [8].

A recent retrospective analysis from Australia involving 199 patients with GC showed that laparoscopy and peritoneal lavage led to treatment changes in 19% of cases (n=37) [9]. Others observed that positive cytology was highly sensitive, and that gross M1 disease may be missed in the absence of visual inspection [10]. Both of these findings are of relevance in the early initiation of chemotherapy for peritoneal disease. Some authors further suggested that once localized peritoneal metastases are identified by SL, sequential intraperitoneal and intravenous paclitaxel plus S-1 are both well-tolerated and associated with promising results [11].

Nevertheless, other authors suggest that SL should not be recommended on a routine basis because of its potential complications and cost. Furthermore, they propose that the indications for SL should include patients fit for laparotomy with endoscopic or radiologic stage cT  $\geq 2$  tumors, suspected but not confirmed stage M1 tumors, and tumors with enlarged (>1 cm) lymph nodes. Palliative laparotomy, rather than SL, is indicated in instances of complications of GC, such as bleeding or gastric outlet obstruction [12].

The potential role for SL in stage IV patients, where only systemic chemotherapy is indicated, has been additionally evaluated by several studies. Tanizawa *et al* [13] studied 30 patients with advanced GC who became resectable candidates after responding favorably to primary chemotherapy. In 20 instances (67%), R0 resections were achieved. The authors concluded that R0 resectability was possible following effective neoadjuvant chemotherapy in the setting of a 41% incidence of postoperative complications. Another study of 15 patients with advanced GC also reported successful downstaging after neoadjuvant chemotherapy. The authors described an increase in R0-resections, a reduction in tumor extension and lymph

node metastases, and a greater possibility of laparoscopic radical gastrectomies [14].

Another critical advantage of SL may be the evaluation of disease resectability after chemotherapy. The need for repeat SL after neoadjuvant therapy was evaluated at Memorial Sloan-Kettering Cancer Center in New York [15]. Of 276 patients with M1 disease, 244 underwent an operation after neoadjuvant therapy within a median time of 105 days; 164 had a second-look SL. SL failed to identify M1 disease in only 1.8% (n=3) of those who underwent laparotomy, prompting the authors to highlight the value of SL in selecting patients with locoregionally advanced gastric tumors for potentially curative resection after neoadjuvant therapy. In contrast to these encouraging findings, scientists from MD Anderson in Texas, based on 3747 patients, concluded that SL does not seem to improve five-year survival [16].

The accuracy of SL in the staging of GC was addressed by Leake *et al* [17]. After reviewing the existing literature, they found a moderate to substantial agreement regarding final pathology for T stage, but only a fair agreement for N stage. In reference to M staging, SL had an overall accuracy, sensitivity, and specificity of 85-98.9%, 64.3-94%, and 80-100%, respectively. The use of diagnostic laparoscopy altered treatment in 8.5-59.6% of cases, avoiding laparotomy in 8.5-43.8% of instances. LUS provided additional benefit in 5.8-7.2% of cases.

The 1<sup>st</sup> St. Gallen EORTC Gastrointestinal Cancer Conference 2012 Expert Panel clearly differentiated treatment and staging recommendations for gastroesophageal cancers. In instances of locally advanced GC ( $\geq T3N+$ ), the preferred treatment modality was defined as pre- and postoperative chemotherapy. Additional recommendations were also made in reference to endosonography, PET-CT scan, laparoscopy for staging and surgical approach [18].

The current Society of American Gastrointestinal and Endoscopic Surgeons guidelines recommend diagnostic laparoscopy for patients with T3/T4 GC without evidence of lymph node involvement or distant metastases on high quality preoperative imaging (Table 1) [3]. The European clinical practice guidelines for GC recommend SL $\pm$  peritoneal washing for malignant cells for all stage IB-III GCs that are deemed to be potentially resectable, with the intent to exclude radiologically occult metastases (level of evidence III, grade of recommendation B) [19]. Further recommendations from

**Table 1** Indications and contraindications for staging laparoscopy (Society of American Gastrointestinal and Endoscopic Surgeons [3])

Indications
Patients with T3-T4 gastric cancer without evidence of N+/M+ on high quality preoperative imaging
Contraindications (Absolute and relative)
Tumors causing complications such as obstruction, hemorrhage or perforation in need of palliative surgery
Early-stage tumors T1/T2 that can proceed directly to resection
History of prior upper abdominal surgery with severe adhesions

several surgical and gastroenterology societies are shown in Table 2 [3,19-25].

### Laparoscopy-assisted peritoneal cytology in GC staging

Several studies have addressed the role of peritoneal cytology as an adjunct to SL for GC [25-30]. The peritoneum represents the most frequent site of GC dissemination, due to migration of malignant cells from the primary tumor onto the peritoneal folds. Peritoneal cytology via laparoscopic peritoneal lavage aims to detect free circulating cancer cells as a way to identify microscopic intra-abdominal spread in the absence of gross dissemination [25]. The most widely used technique consists of saline irrigation of the pelvis and re-aspiration of the peritoneal fluid [29]. Laboratory methods for malignant cell detection in the aspirate include conventional cytology and, more recently, reverse transcriptase-polymerase chain reaction (rt-PCR) [30].

Surgery of therapeutic intent was considered futile in the presence of malignant cells by cytological evaluation. Recently, however, M1 disease of the peritoneum (pM1) has been further subdivided into either overt metastatic spread with macroscopic peritoneal deposits witnessed by SL (P+), or positive cytology for free circulating cancer cells in the peritoneal aspirate (Cyt+) [31]. Thus, patients with locally advanced GC are further stratified into four distinct subgroups based on peritoneal involvement: P+/Cyt+, P+/Cyt-, P-/Cyt+ and P-/Cyt-. Overt peritoneal disease by SL (P+) is considered advanced disease [32] that should be managed with palliative care. On the other hand, negative macroscopic peritoneal dissemination with positive cytology (P-/Cyt+) remains highly controversial.

Early investigators postulated that positive cytology by laparoscopic lavage, even in the absence of gross peritoneal disease, constituted a contraindication for curative resection [25]. Wilkiemeyer *et al* demonstrated that laparoscopic assessment of gross disease was sufficient to

accurately stratify patients into either curative or palliative management [32]; Nieveen *et al* showed that peritoneal cytology conferred a 1.3% prognostic benefit when compared to conventional SL alone [33].

Lee *et al*, however, after retrospectively evaluating 1072 patients operated for gastric adenocarcinoma, concluded that P-/Cyt+ patients had a significantly better prognosis than P+/Cyt+ patients. The finding was attributed to the aggressiveness of surgical resection and the efficacy of postoperative chemotherapy [34]. In a study by Lorenzen *et al*, a subset of P-/Cyt+ patients that converted to P-/Cyt- after neoadjuvant therapy ultimately achieved better survival after surgery compared to non-converted Cyt+ patients [35]. Mezhir *et al* proposed a new management algorithm for P-/Cyt+. After an initial SL with peritoneal cytology, neoadjuvant chemotherapy was administered, and reassessment by a second SL with lavage cytology was carried out 3-6 months later. Patients who reverted to P-/Cyt- benefited from gastrectomy if fit for surgery [28].

Notably, the reported sensitivity of conventional peritoneal lavage cytology for the detection of peritoneal disease varies greatly, from 26-70.8%, while its specificity varies from 70.8-100% [26,32,33]. As far as the overall accuracy of the cytology examination is concerned, it has received a lot of criticism because of its variability, the reported range being between 22% and 30% in GC [26]. Non-standardized methods of peritoneal lavage, as well as interobserver bias among pathologists' interpretations, can be held responsible for this phenomenon [26]. Interestingly, a study by Kodera *et al* compared conventional peritoneal lavage cytology to rt-PCR in patients with GC. The authors reported that the PCR technique improved the sensitivity of positive identification of malignant cells from 37% to a remarkable 77% [36].

Recent developments in cancer chemotherapy have improved the outcome of the cytology-positive population to the point where a certain proportion of these patients survive 5 years with radical surgery followed by chemotherapy. Thus, there is certainly a role for surgery in patients with minimal peritoneal metastases, both in clinical practice and in clinical

**Table 2** Recommendations for staging laparoscopy from various societies

Society	Country of origin	Recommendation
SAGES [3]	USA	Patients with T3 or T4 gastric cancer without evidence of lymph node or distant metastases on high-quality preoperative imaging
ESMO [19]	Europe	All patients with resectable gastric cancer [III, Grade B]
S3 Guidelines [20]	Germany	Patients with advanced-stage gastric cancer (cT3-cT4) [II-III, Grade B]
GIRCG [21]	Italy	Cases deemed to be at risk of peritoneal carcinomatosis not visible or doubtful at CT examination
AUGIS BSG BASO [22]	UK & Ireland	All gastric cancers and in selected patients with lower esophageal and esophagogastric junctional tumors (Grade C)
SEOM [23]	France	All patients with potentially resectable gastric cancer
JGCA [24]	Japan	Patients with clinical stage II-III prior to neo-adjuvant treatment

SAGES, Society of American Gastrointestinal and Endoscopic Surgeons; ESMO, European Society for Medical Oncology; GIRCG, The Italian Research Group for Gastric Cancer; AUGIS, Association of Upper Gastrointestinal Surgeons of Great Britain and Ireland; BSG, British Society of Gastroenterology; BASO, British Association of Surgical Oncology; SEOM, Spanish Society of Clinical Oncology; JGCA, Japanese

trials, where surgery in combination with various types of chemotherapy remains the only hope for cure [37].

## LUS

LUS has been introduced as an adjunct to diagnostic laparoscopy. LUS allows further delineation of tumor depth, invasion of adjacent organs, lymph node involvement, and assessment of liver metastatic disease. Its role, although well established in staging hepatobiliary and pancreatic cancers, still remains debatable in the preoperative assessment of GCs. The Society of American Gastrointestinal and Endoscopic Surgeons (SAGES) [38] recommends that LUS should be employed when SL is undertaken.

Initial reports [39-41] suggested that LUS was more accurate than CT in GC staging. Further studies did not always concur with this view. Romijn *et al* [42] evaluated 20 patients with adenocarcinoma of the gastric cardia. Four patients were noted to have metastatic disease during initial standard preoperative evaluation. The number increased to eight after implementation of LUS. In a retrospective study comparing preoperative findings in 320 patients [43], LUS increased the detection rate of metastases by 8%, changing their management from surgical resection to palliation. Lavonius *et al* [44] concluded that no additional information obtained by LUS would have changed either the staging or the decision to proceed with laparotomy. A similar experience was reported by Velasco *et al* [45]. Wakelin *et al* [46] proposed that, although LUS may have had an additional benefit in patients with distal early stage GCs, endoscopic ultrasound remained the best staging modality when early (T1/T2) proximal tumors were investigated. Hulscher *et al* evaluated patients who presented with tumors of the gastric cardia. Laparoscopy with ultrasonography safely detected metastases not shown by conventional staging investigations in 23% of cases [47]. A more recent prospective study by Muntean *et al* [48] mentioned that, although LUS appeared to be accurate in the staging of early GC, it did not impact operative management.

In conclusion, LUS constitutes a useful adjunct to diagnostic laparoscopy and can complement other imaging modalities, such as endoscopic ultrasound and CT, in staging GCs. Based on the results of our literature review, it could be argued that LUS in conjunction with SL constitutes a very useful but not indispensable staging tool.

## SL compared to other staging modalities

### CT, 18 FDG-PET/CT vs. SL

Burbidge *et al* compared CT to SL in 52 patients and found that CT was highly specific but not sufficiently sensitive to detect or exclude peritoneal disease. Nine patients (25%) had metastases at surgery; 30-45% of peritoneal and hepatic metastases were misdiagnosed by CT or other preoperative imaging methods [49].

De Graaf *et al* [50] from Nottingham proposed that combined CT and EUS was a better predictor of tumor resectability than CT alone (81% vs. 65%) in esophagogastric tumors. Interestingly, 20.2% of subjects in this study avoided unnecessary operations. SL was an essential adjunct to imaging in all patients being considered for curative surgery. Krasna *et al* [51] reported that laparoscopy provided better information regarding local tumor invasion and peritoneal metastases than CT and EUS combined. SL was found to be an essential adjunct to imaging in all GC patients being considered for curative surgery.

The cost of SL was benchmarked only against fludeoxyglucose (<sup>18</sup>F-FDG) PET/CT, a staging method able to identify occult metastatic lesions in approximately 10% of patients with locally advanced GC [52]. The high positive predictive value of <sup>18</sup>F-FDG PET/CT might make it beneficial in the evaluation of patients with suspected lymphatic involvement. Its sensitivity and specificity in the detection of lymph node metastases have been reported to be 41-51% and 86-100%, respectively [53]. A possible explanation for the low sensitivity regarding peritoneal spread detection in GC could be either the small size of the peritoneal lesions (<5 mm), or the presence of extensive reactive fibrosis around them. In fact, the higher maximum standardized uptake value of primary GC correlated with both non-curative surgery and lymph node metastases [54]. Alternatively, acute inflammation such as gastritis can lead to false-positive FDG uptake. The role of <sup>18</sup>F-FDG PET/CT seems to be limited to the early stages and to signet ring cell carcinomas because of their lower <sup>18</sup>F-FDG uptake [55].

Kaneko *et al* performed a retrospective analysis of all GC patients who underwent staging <sup>18</sup>F-FDG PET scans from 2002 to 2013 at their institution, and reviewed the existing literature [56]. They described four predictors of high tumor <sup>18</sup>F-FDG avidity, including advanced tumor stage, large tumor size (>3 cm), non-signet ring cell carcinoma, and glucose transporter 1-positive expression on immunohistochemistry. Based on these observations, they proposed a PET scoring system to define indications for <sup>18</sup>F-FDG PET scanning in GC [56].

In a study by Mirza *et al*, SL altered the treatment plan in 17% (n=64/387) of stomach and gastroesophageal junction tumor patients with negative CT and FDG-PET scans. Diagnostic laparoscopy was especially useful for detecting and confirming nodal involvement and distant metastatic disease not evident on CT and FDG-PET [57].

### EUS vs. SL

EUS is widely thought to be the most accurate non-surgical method for T staging. Precise images are obtained by placing the probe at or near the target tissue, avoiding interference from abdominal fat, bones, or bowel gas. EUS can define the different layers of the gastric wall, making it possible to accurately determine the depth of tumor invasion [58-60]. EUS can also evaluate localized lymphadenopathy, providing

information about features (such as round shape, hypoechotexture, sharp borders, and size >1 cm) suggestive of malignant involvement [61]. Evaluation of adjacent organs can provide further precise additional information [58,62].

A recent systematic review and meta-analysis of the utility of EUS for preoperative staging in GC reported a diagnostic accuracy for overall T staging of 56.9-87.7% (pooled accuracy of 75%) [63]. Pooled T1, T2, T3, and T4 accuracy rates were 77%, 65%, 85%, and 79%, respectively. For N staging, diagnostic accuracy was 30-90%, pooled accuracy 64%, pooled sensitivity 74%, and pooled specificity 80%. The authors concluded that EUS was best when evaluating tumor invasion (especially T3 and T4 disease) rather than nodal status [63]. Puli *et al* evaluated 22 studies (1986-2006) and reported better EUS accuracy in advanced T-stages [64].

Nevertheless, EUS has some limitations; it has been found to be highly operator-dependent, requiring extensive training and experience [65]. The interpretation of findings, especially in the setting of distorted gastric layers due to peptic ulceration, can be highly challenging, whereas fibrous proliferation in reaction to benign peptic ulcers can be often indistinguishable from fibrotic changes induced by malignant invasion [66,67]. Moreover, inflammation and fibrosis in ulcerated lesions obscure tumor identification and can cause overstaging, while understaging results when tumor micro-infiltration is not identified.

Despite advances in CT and magnetic resonance imaging techniques, EUS remains the procedure of choice for T staging, especially for non-stenotic gastroesophageal tumors. Although EUS cannot replace SL, it is a valuable examination that enhances the indications (T3-4, N+) for further staging through SL prior to laparotomy.

### SL and intraperitoneal chemotherapy

The role and indications of hyperthermic intraperitoneal chemotherapy (HIPEC) for GC are not clearly established. In most cases, HIPEC has been combined with cytoreductive surgery (CRS). A meta-analysis by Sun *et al* demonstrated that HIPEC improved overall survival in patients who underwent resection for advanced GC, and prevented peritoneal local recurrence among those with serosal invasion [68].

HIPEC has been used as an adjuvant therapy after curative surgery, along with CRS for peritoneal carcinomatosis (PC), and as palliation for PC with refractory ascites [69]. Some promising studies referred to the so-called bidirectional chemotherapy prior to CRS and HIPEC. The proposed therapeutic regimen of neoadjuvant intraperitoneal and systemic chemotherapy has had encouraging results in the setting of good pathologic response and a peritoneal cancer index (PCI)  $\leq 6$  [70,71].

More recently, the Peritoneal Surface Oncology Group International (PSOGI) proposed a new treatment protocol based on neoadjuvant bidirectional intraperitoneal/systemic chemotherapy (BISIC). In this modality, PCI was determined laparoscopically and neoadjuvant BISIC initiated two weeks later. After three cycles of BISIC,

laparotomy and peritonectomy combined with HIPEC were undertaken [72]. Laparoscopy defined the indications for intraperitoneal chemotherapy and estimated the PCI. It also allowed for the placement of peritoneal drains and for the evaluation of peritoneal lesions after HIPEC.

### Concluding remarks

The role of laparoscopy and especially SL in GC is crucial. The diagnosis of intra-abdominal disease by SL is essential to determine the most appropriate treatment regimen. SL also complements preoperative imaging studies characterized by their limited ability to identify regional extension of the primary tumors and/or metastatic/peritoneal disease. Furthermore, SL facilitates obtaining biopsies, performing intraoperative ultrasound examinations, and executing therapeutic interventions.

### References

1. Popova TN, Korzhenskii FP, Aleksandrova MI. [The use of laparoscopy in the staging of stomach cancer]. *Vopr Onkol* 1987;**33**:75-78.
2. Feussner H, Kraemer SJ, Siewert JR. [The technique of laparoscopic ultrasound study in diagnostic laparoscopy]. *Langenbecks Arch Chir* 1994;**379**:248-254.
3. <https://www.sages.org/publications/guidelines/guidelines-for-diagnostic-laparoscopy/>, Board of Governors of the Society of American Gastrointestinal and Endoscopic Surgeons (SAGES), 2010.
4. Chang L, Stefanidis D, Richardson WS, Earle DB, Fanelli RD. The role of staging laparoscopy for intraabdominal cancers: an evidence-based review. *Surg Endosc* 2009;**23**:231-241.
5. Grundmann RT, Hölscher AH, Bembek A, et al. [Diagnosis of and therapy for gastric cancer--work-flow]. *Zentralbl Chir* 2009;**134**:362-374.
6. Kaiser GM, Sotiropoulos GC, Frühauf NR, et al. Value of staging laparoscopy for multimodal therapy planning in esophago-gastric cancer. *Int Surg* 2007;**92**:128-132.
7. Karanicolas PJ, Elkin EB, Jacks LM, et al. Staging laparoscopy in the management of gastric cancer: a population-based analysis. *J Am Coll Surg* 2011;**213**:644-651.
8. Oida T, Kano H, Mimatsu K, et al. Technical considerations in laparoscopic staging for advanced gastric cancer. *Hepatogastroenterology* 2012;**59**:164-167.
9. Tourani SS, Cabalag C, Link E, Chan ST, Duong CP. Laparoscopy and peritoneal cytology: important prognostic tools to guide treatment selection in gastric adenocarcinoma. *ANZ J Surg* 2015;**85**:69-73.
10. Mezhir JJ, Posner MC, Roggin KK. Prospective clinical trial of diagnostic peritoneal lavage to detect positive peritoneal cytology in patients with gastric cancer. *J Surg Oncol* 2013;**107**:794-798.
11. Imano M, Yasuda A, Itoh T, et al. Phase II study of single intraperitoneal chemotherapy followed by systemic chemotherapy for gastric cancer with peritoneal metastasis. *J Gastrointest Surg* 2012;**16**:2190-2196.
12. Sarela AI, Lefkowitz R, Brennan MF, Karpeh MS. Selection of patients with gastric adenocarcinoma for laparoscopic staging. *Am J Surg* 2006;**191**:134-138.

13. Tanizawa Y, Terashima M, Tokunaga M, et al. [Conversion therapy of stage IV gastric cancer]. *Gan To Kagaku Ryoho* 2012;**39**:2469-2473.
14. Zhou DL, Zheng CZ, Li JH, et al. [Application of neoadjuvant chemotherapy in laparoscopic gastrectomy for advanced gastric cancer]. *Zhonghua Wei Chang Wai Ke Za Zhi* 2009;**12**:126-129.
15. Cardona K, Zhou Q, Gönen M, et al. Role of repeat staging laparoscopy in locoregionally advanced gastric or gastroesophageal cancer after neoadjuvant therapy. *Ann Surg Oncol* 2013;**20**:548-554.
16. Badgwell B, Cormier JN, Krishnan S, et al. Does neoadjuvant treatment for gastric cancer patients with positive peritoneal cytology at staging laparoscopy improve survival? *Ann Surg Oncol* 2008;**15**:2684-2691.
17. Leake PA, Cardoso R, Seevaratnam R, et al. A systematic review of the accuracy and indications for diagnostic laparoscopy prior to curative-intent resection of gastric cancer. *Gastric Cancer* 2012;**15**(Suppl 1):S38-S47.
18. Lutz MP, Zalberg JR, Ducreux M, et al; First St Gallen EORTC Gastrointestinal Cancer Conference 2012 Expert Panel. Highlights of the EORTC St. Gallen International Expert Consensus on the primary therapy of gastric, gastroesophageal and oesophageal cancer - differential treatment strategies for subtypes of early gastroesophageal cancer. *Eur J Cancer* 2012;**48**:2941-2953.
19. Smyth EC, Verheij M, Allum W, Cunningham D, Cervantes A, Arnold D; ESMO Guidelines Committee. Gastric cancer: ESMO Clinical Practice Guidelines for diagnosis, treatment and follow-up. *Ann Oncol* 2016;**27**:v38-v49.
20. Moehler M, Al-Batran SE, Andus T, et al. German S3-guideline "Diagnosis and treatment of esophagogastric cancer". *Z Gastroenterol* 2011;**49**:461-531.
21. De Manzoni G, Marrelli D, Baiocchi GL, et al. The Italian Research Group for Gastric Cancer (GIRCG) guidelines for gastric cancer staging and treatment: 2015. *Gastric Cancer* 2017;**20**:20-30.
22. Allum WH, Blazeby JM, Griffin SM, Cunningham D, Jankowski JA, Wong R; Association of Upper Gastrointestinal Surgeons of Great Britain and Ireland, the British Society of Gastroenterology and the British Association of Surgical Oncology. Guidelines for the management of oesophageal and gastric cancer. *Gut* 2011;**60**:1449-1472.
23. Rivera F, Grávalos C, García-Carbonero R; SEOM (Spanish Society of Clinical Oncology). SEOM clinical guidelines for the diagnosis and treatment of gastric adenocarcinoma. *Clin Transl Oncol* 2012;**14**:528-535.
24. Japanese Gastric Cancer Association. Japanese gastric cancer treatment guidelines 2010 (ver. 3). *Gastric Cancer* 2011;**14**:113-123.
25. Bryan RT, Cruickshank NR, Needham SJ, et al. Laparoscopic peritoneal lavage in staging gastric and oesophageal cancer. *Eur J Surg Oncol* 2001;**27**:291-297.
26. Chuwa EW, Khin LW, Chan WH, Ong HS, Wong WK. Prognostic significance of peritoneal lavage cytology in gastric cancer in Singapore. *Gastric Cancer* 2005;**8**:228-237.
27. La Torre M, Ferri M, Giovagnoli MR, et al. Peritoneal wash cytology in gastric carcinoma. Prognostic significance and therapeutic consequences. *Eur J Surg Oncol* 2010;**36**:982-986.
28. Mezhir JJ, Shah MA, Jacks LM, Brennan MF, Coit DG, Strong VE. Positive peritoneal cytology in patients with gastric cancer: natural history and outcome of 291 patients. *Ann Surg Oncol* 2010;**17**:3173-3180.
29. Nath J, Moorthy K, Taniere P, Hallissey M, Alderson D. Peritoneal lavage cytology in patients with oesophagogastric adenocarcinoma. *Br J Surg* 2008;**95**:721-726.
30. Frattini F, Rauseri S, Chiappa C, Rovera F, Boni L, Dionigi G. Prognosis and treatment of patients with positive peritoneal cytology in advanced gastric cancer. *World J Gastrointest Surg* 2013;**5**:135-137.
31. Edge SB BD, Compton CC. AJCC Cancer staging manual. 7th ed. New York: Springer, 2010.
32. Wilkemyer MB, Bieligg SC, Ashfaq R, Jones DB, Rege RV, Fleming JB. Laparoscopy alone is superior to peritoneal cytology in staging gastric and esophageal carcinoma. *Surg Endosc* 2004;**18**:852-856.
33. Nieveen van Dijkum EJ, Sturm PD, de Wit LT, Offerhaus J, Obertop H, Gouma DJ. Cytology of peritoneal lavage performed during staging laparoscopy for gastrointestinal malignancies: is it useful? *Ann Surg* 1998;**228**:728-733.
34. Lee SD, Ryu KW, Eom BW, Lee JH, Kook MC, Kim YW. Prognostic significance of peritoneal washing cytology in patients with gastric cancer. *Br J Surg* 2012;**99**:397-403.
35. Lorenzen S, Panzram B, Rosenberg R, et al. Prognostic significance of free peritoneal tumor cells in the peritoneal cavity before and after neoadjuvant chemotherapy in patients with gastric carcinoma undergoing potentially curative resection. *Ann Surg Oncol* 2010;**17**:2733-2739.
36. Kodera Y, Nakanishi H, Ito S, et al. Quantitative detection of disseminated cancer cells in the greater omentum of gastric carcinoma patients with real-time RT-PCR: a comparison with peritoneal lavage cytology. *Gastric Cancer* 2002;**5**:69-76.
37. Kodera Y. Gastric cancer with minimal peritoneal metastasis: is this a sign to give up or to treat more aggressively? *Nagoya J Med Sci* 2013;**75**:3-10.
38. Richardson W, Stefanidis D, Mittal S, Fanelli RD. SAGES guidelines for the use of laparoscopic ultrasound. *Surg Endosc* 2010;**24**:745-756.
39. Conlon KC, Karpeh MS Jr. Laparoscopy and laparoscopic ultrasound in the staging of gastric cancer. *Semin Oncol* 1996;**23**:347-351.
40. Finch MD, John TG, Garden OJ, Allan PL, Paterson-Brown S. Laparoscopic ultrasonography for staging gastroesophageal cancer. *Surgery* 1997;**121**:10-17.
41. Anderson DN, Campbell S, Park KG. Accuracy of laparoscopic ultrasonography in the staging of upper gastrointestinal malignancy. *Br J Surg* 1996;**83**:1424-1428.
42. Romijn MG, van Overhagen H, Spillenaar Bilgen EJ, Ijzermans JN, Tilanus HW, Laméris JS. Laparoscopy and laparoscopic ultrasonography in staging of oesophageal and cardiac carcinoma. *Br J Surg* 1998;**85**:1010-1012.
43. Samee A, Moorthy K, Jaipersad T, et al. Evaluation of the role of laparoscopic ultrasonography in the staging of oesophagogastric cancers. *Surg Endosc* 2009;**23**:2061-2065.
44. Lavonius MI, Gullichsen R, Salo S, Sonninen P, Ovaska J. Staging of gastric cancer: a study with spiral computed tomography, ultrasonography, laparoscopy, and laparoscopic ultrasonography. *Surg Laparosc Endosc Percutan Tech* 2002;**12**:77-81.
45. Velasco JM, Rossi H, Hieken TJ, Fernandez M. Laparoscopic ultrasound enhances diagnostic laparoscopy in the staging of intra-abdominal neoplasms. *Am Surg* 2000;**66**:407-411.
46. Wakelin SJ, Deans C, Crofts TJ, Allan PL, Plevris JN, Paterson-Brown S. A comparison of computerised tomography, laparoscopic ultrasound and endoscopic ultrasound in the preoperative staging of oesophago-gastric carcinoma. *Eur J Radiol* 2002;**41**:161-167.
47. Hulscher JB, Nieveen van Dijkum EJ, de Wit LT, et al. Laparoscopy and laparoscopic ultrasonography in staging carcinoma of the gastric cardia. *Eur J Surg* 2000;**166**:862-865.
48. Muntean V, Mihailov A, Iancu C, et al. Staging laparoscopy in gastric cancer. Accuracy and impact on therapy. *J Gastrointest Liver Dis* 2009;**18**:189-195.
49. Burbidge S, Mahady K, Naik K. The role of CT and staging laparoscopy in the staging of gastric cancer. *Clin Radiol* 2013;**68**:251-255.
50. de Graaf GW, Ayantunde AA, Parsons SL, Duffy JB, Welch NT. The role of staging laparoscopy in oesophagogastric cancers. *Eur J Surg*

- Oncol* 2007;**33**:988-992.
51. Krasna MJ, Jiao X, Mao YS, et al. Thoracoscopy/laparoscopy in the staging of esophageal cancer: Maryland experience. *Surg Laparosc Endosc Percutan Tech* 2002;**12**:213-218.
  52. Smyth E, Schöder H, Strong VE, et al. A prospective evaluation of the utility of 2-deoxy-2-[(18) F]fluoro-D-glucose positron emission tomography and computed tomography in staging locally advanced gastric cancer. *Cancer* 2012;**118**:5481-5488.
  53. Kim EY, Lee WJ, Choi D, et al. The value of PET/CT for preoperative staging of advanced gastric cancer: comparison with contrast-enhanced CT. *Eur J Radiol* 2011;**79**:183-188.
  54. Choi JY, Shim KN, Kim SE, Jung HK, Jung SA, Yoo K. The clinical value of 18F-fluorodeoxyglucose uptake on positron emission tomography/computed tomography for predicting regional lymph node metastasis and non-curative surgery in primary gastric carcinoma. *Korean J Gastroenterol* 2014;**64**:340-347.
  55. Filik M, Kir KM, Aksel B, et al. The Role of 18F-FDG PET/CT in the Primary Staging of Gastric Cancer. *Mol Imaging Radionucl Ther* 2015;**24**:15-20.
  56. Kaneko Y, Murray WK, Link E, Hicks RJ, Duong C. Improving patient selection for 18F-FDG PET scanning in the staging of gastric cancer. *J Nucl Med* 2015;**56**:523-529.
  57. Mirza A, Galloway S. Laparoscopy, computerised tomography and fluorodeoxyglucose positron emission tomography in the management of gastric and gastro-oesophageal junction cancers. *Surg Endosc* 2016;**30**:2690-2696.
  58. Dittler HJ, Siewert JR. Role of endoscopic ultrasonography in gastric carcinoma. *Endoscopy* 1993;**25**:162-166.
  59. Bentrem D, Gerdes H, Tang L, Brennan M, Coit D. Clinical correlation of endoscopic ultrasonography with pathologic stage and outcome in patients undergoing curative resection for gastric cancer. *Ann Surg Oncol* 2007;**14**:1853-1859.
  60. Botet JF, Lightdale CJ, Zauber AG, et al. Preoperative staging of gastric cancer: comparison of endoscopic US and dynamic CT. *Radiology* 1991;**181**:426-432.
  61. Tio TL, Kallimanis GE. Endoscopic ultrasonography of perigastrointestinal lymph nodes. *Endoscopy* 1994;**26**:776-779.
  62. Kelly S, Harris KM, Berry E, et al. A systematic review of the staging performance of endoscopic ultrasound in gastro-oesophageal carcinoma. *Gut* 2001;**49**:534-539.
  63. Cardoso R, Coburn N, Seevaratnam R, et al. A systematic review and meta-analysis of the utility of EUS for preoperative staging for gastric cancer. *Gastric Cancer* 2012;**15**(Suppl 1):S19-S26.
  64. Puli SR, Batapati Krishna Reddy J, Bechtold ML, Antillon MR, Ibdah JA. How good is endoscopic ultrasound for TNM staging of gastric cancers? A meta-analysis and systematic review. *World J Gastroenterol* 2008;**14**:4011-4019.
  65. Pollack BJ, Chak A, Sivak MV Jr. Endoscopic ultrasonography. *Semin Oncol* 1996;**23**:336-346.
  66. Shimizu S, Tada M, Kawai K. Endoscopic ultrasonography for early gastric cancer. *Endoscopy* 1994;**26**:767-768.
  67. Ohashi S, Nakazawa S, Yoshino J. Endoscopic ultrasonography in the assessment of invasive gastric cancer. *Scand J Gastroenterol* 1989;**24**:1039-1048.
  68. Sun J, Song Y, Wang Z, et al. Benefits of hyperthermic intraperitoneal chemotherapy for patients with serosal invasion in gastric cancer: a meta-analysis of the randomized controlled trials. *BMC Cancer* 2012;**12**:526.
  69. Seshadri RA, Glehen O. Cytoreductive surgery and hyperthermic intraperitoneal chemotherapy in gastric cancer. *World J Gastroenterol* 2016;**22**:1114-1130.
  70. Yonemura Y, Elnemr A, Endou Y, et al. Effects of neoadjuvant intraperitoneal/systemic chemotherapy (bidirectional chemotherapy) for the treatment of patients with peritoneal metastasis from gastric cancer. *Int J Surg Oncol* 2012;**2012**:148420.
  71. Canbay E, Mizumoto A, Ichinose M, et al. Outcome data of patients with peritoneal carcinomatosis from gastric origin treated by a strategy of bidirectional chemotherapy prior to cytoreductive surgery and hyperthermic intraperitoneal chemotherapy in a single specialized center in Japan. *Ann Surg Oncol* 2014;**21**:1147-1152.
  72. Coccolini F, Celotti A, Ceresoli M, et al. Hyperthermic intraperitoneal chemotherapy (HIPEC) and neoadjuvant chemotherapy as prophylaxis of peritoneal carcinosis from advanced gastric cancer-effects on overall and disease free survival. *J Gastrointest Oncol* 2016;**7**:523-529.