

Type 1 autoimmune hepatitis presenting with severe autoimmune neutropenia

Petros Doumtsīs^a, Theodora Oikonomou^a, Ioannis Goulis^a, Kaliopi Zachou^b, George Dalekos^b, Evangelos Cholongitas^a

Hippokration General Hospital, Medical School, Aristotle University of Thessaloniki; Medical School, University of Thessaly, Larissa, Greece

Abstract

Autoimmune hepatitis (AIH) is a progressive, chronic liver disease characterized by unresolving hepatocellular inflammation of autoimmune origin. The clinical spectrum may vary from asymptomatic presentation, to non-specific symptoms such as fatigue, arthralgias, nausea and abdominal pain, to acute severe liver disease. AIH is characterized by the presence of interface hepatitis and portal plasma cell infiltration on histological examination, hypergammaglobulinemia, and positive autoantibodies. AIH is associated with other autoimmune diseases and its course is often accompanied by various non-specific hematological disorders. However, the coexistence of autoimmune neutropenia (AIN) is infrequent. We present a case of a female patient diagnosed with type 1 AIH and agranulocytosis on presentation. A diagnosis of AIN was established, based on the patient's sex, the underlying liver disease, the absence of alternative causes, the presence of atypical anti-neutrophil cytoplasmic antibodies in patient's serum and the favorable and dose-dependent treatment of both pathologic entities with corticosteroids and mycophenolate mofetil.

Keywords Agranulocytosis, autoimmune neutropenia, autoimmune hepatitis, anti-neutrophil cytoplasmic antibodies, chronic hepatitis, corticosteroids, mycophenolate mofetil

Ann Gastroenterol 2017; 30 (5): 1-4

Introduction

Autoimmune hepatitis (AIH) is a chronic relapsing liver disease characterized by hepatocellular inflammation caused by a combination of genetic failure of immune tolerance and environmental triggers. AIH is associated with the presence of interface hepatitis and portal plasma cell infiltration on histological examination, hypergammaglobulinemia and positive autoantibodies. A strong association of AIH with other autoimmune diseases has been reported. Concomitant

hematological disorders, such as autoimmune hemolytic anemia, autoimmune thrombocytopenia and moderate leucopenia, are well documented. Nevertheless, the coexistence of severe neutropenia is very rare [5-7]. We present a patient with severe isolated agranulocytosis at the time of AIH diagnosis, with antineutrophil autoantibodies detected in the blood.

Case report

A 59-year-old female presented with non-specific right upper quadrant abdominal pain and intermittent fever with axillary temperature up to 37.9°C for a week, accompanied by mild arthralgias and general fatigue. She did not mention any history of prescription, herbal or over-the-counter medication, or consumption of alcohol or illicit drugs. Her medical history included a laparoscopic cholecystectomy 7 years previously because of acute calculous cholecystitis. She had no previous history of tattoos, no noteworthy allergies and no family history of liver, autoimmune or hematological disease. The results of the physical examination were unremarkable, except for mild icteric sclera and mild tenderness upon palpation of right upper quadrant of the abdomen without muscle tension.

Laboratory tests indicated acute hepatocellular liver injury with intrahepatic cholestasis. Specific values included aspartate aminotransferase 467 U/L (upper limits of normal [ULN]

^a4th Department of Internal Medicine, Hippokration General Hospital, Medical School Aristotle University of Thessaloniki (Petros Doumtsīs, Evangelos Cholongitas, Theodora Oikonomou, Ioannis Goulis);

^bDepartment of Medicine and Research Laboratory of Internal Medicine, Medical School, University of Thessaly, Larissa (Kaliopi Zachou, George Dalekos), Greece

Conflict of Interest: None

Correspondence to: Evangelos Cholongitas, Assistant Professor of Internal Medicine, 4th Department of Internal Medicine, Medical School of Aristotle University, Hippokration General Hospital of Thessaloniki, 49, Konstantinopoleos Str., 54642 Thessaloniki, Greece, e-mail: cholongitas@yahoo.gr

Received 9 June 2017; accepted 18 July 2017;
published online 4 August 2017

DOI: <https://doi.org/10.20524/aog.2017.0186>

© 2017 Hellenic Society of Gastroenterology

www.annalsgastro.gr

<37 U/L), alanine aminotransferase 539 U/L (ULN<45 U/L), alkaline phosphatase 134 U/L (ULN<120 U/L), γ -glutamyl transferase 162 U/L (ULN<38 U/L), total bilirubin 4.05 mg/dL (ULN<1.2 mg/dL), direct bilirubin 2.08 mg/dL (ULN<0.2 mg/dL), total protein 8.8 g/dL (normal values: 6.6-8.3 g/dL), albumin 3.6 g/dL (normal values: 3.5-5.2 g/dL), prothrombin time 11.6 sec, international normalized ratio 0.98. On presentation, the patient's hemogram revealed mild leucopenia ($3.30 \times 10^9/\mu\text{L}$) with severe isolated neutropenia (absolute neutrophil count [ANC] 554/L), with normal hematocrit (40.6%) and platelet count ($208 \times 10^9/\text{L}$). A peripheral smear showed decreased neutrophils. The patient was admitted and further investigation ensued.

Abdominal ultrasound showed marginal splenomegaly (13 cm) without hepatomegaly. Abdominal magnetic resonance imaging and magnetic resonance cholangiopancreatography revealed neither abnormal dilation of bile ducts nor filling defects. Serological markers for hepatitis A, B and C, cytomegalovirus, Epstein-Barr virus, herpes simplex viruses, parvovirus B19, human herpes virus 6, HIV, toxoplasma,

brucella, leishmania and mycoplasma were all negative. Mildly elevated ceruloplasmin levels and normal copper levels ruled out Wilson's disease, while normal transferrin saturation and serum ferritin levels discarded hemochromatosis.

Serum protein electrophoresis revealed polyclonal hypergammaglobulinemia with elevated IgG levels (3440 mg/dL). Antinuclear antibodies (ANA 1/320), anti-smooth muscle antibodies (ASMA 1/640) and atypical antineutrophil cytoplasmic antibodies (atypical pANCA – pANNA 1/320) were detected. The patient's serum was negative for rheumatoid factor, anti-cyclic citrullinated peptide antibody, antibodies to extractable nuclear antigens, lupus anticoagulant, anti-cardiolipin and antiphospholipid autoantibodies. Serum levels of complement components and anti- β 2GPI antibodies were normal. The patient was positive for anti-double-stranded DNA autoantibodies (199 U/mL). Given their well-documented presence in cases of ANA-positive type 1 autoimmune hepatitis, the rarity of liver involvement in systemic lupus erythematosus (SLE) and the lack of other

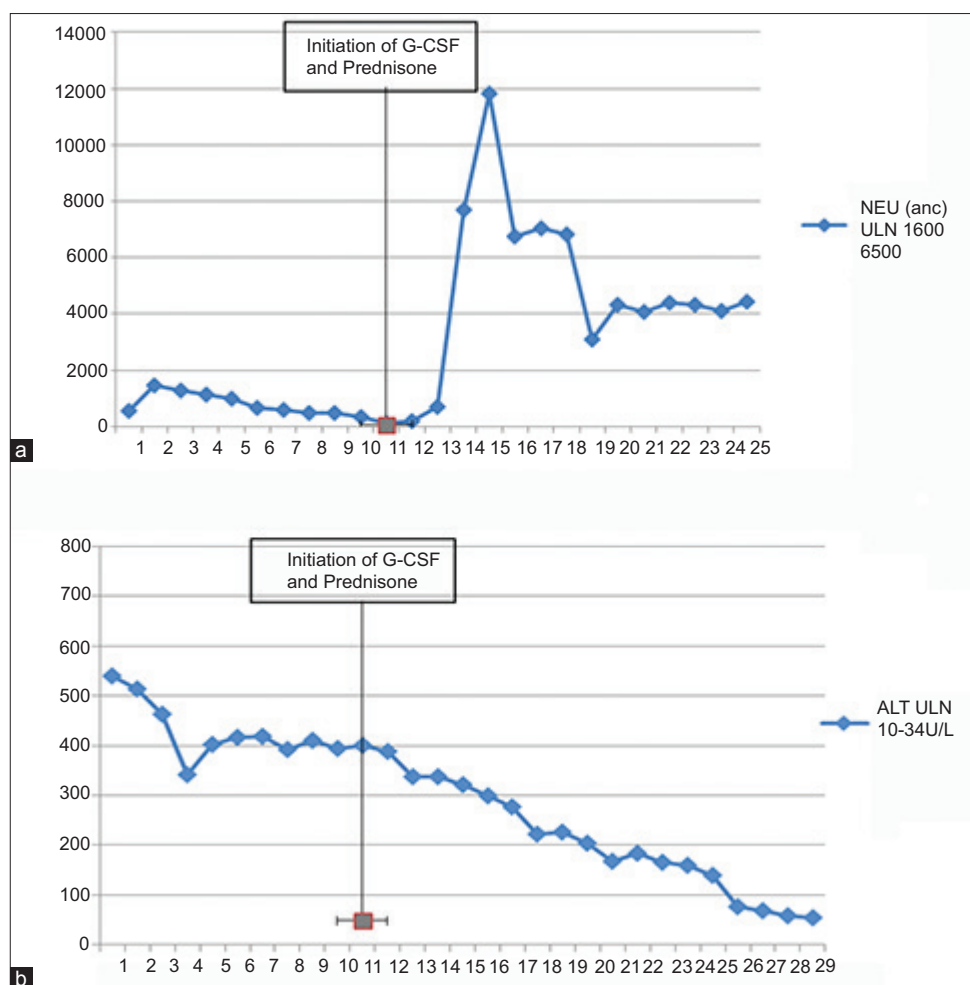


Figure 1 (A) Daily evolution of neutrophils (ANC) during hospitalization. Prednisone regimen and G-CSF were initiated on the 10th day. G-CSF was given for 2 consecutive days. (B) Daily evolution of ALT (measured in IU/L) during hospitalization. Prednisone regimen and G-CSF were initiated on the 10th day. G-CSF was given for 2 consecutive days

ALT, alanine aminotransferase; ANC, absolute neutrophil count; G-CSF, granulocyte-stimulating growth factor; NEU, neutrophils; ULN, upper limit of normal

characteristic extrahepatic manifestations, neither SLE nor other rheumatologic disease could be diagnosed definitively.

Since the patient refused any invasive diagnostic techniques, neither a liver biopsy nor a bone marrow biopsy was performed. No further investigation to evaluate the patient's neutropenia, including flow cytometry with peripheral blood, was pursued. Using both the revised original scoring system of the International Autoimmune Hepatitis Group (IAHG) [4] and the simplified criteria for the diagnosis of AIH [5] we ended with scores (10 for the former system and 6 for the simplified score) indicative of probable AIH. A diagnosis of type 1 AIH (AIH-1) and concomitant autoimmune neutropenia (AIN) was established [6-8].

Having presented with a severe neutropenia, the patient showed no improvement, with the lowest value (ANC 102/L) recorded during her 10th day of hospitalization. She was started on prednisone (60 mg/day) and a daily dose of granulocyte-colony stimulating factor for two successive days until neutrophils were properly raised. A progressive normalization of serum transaminases and a gradual stabilization of neutrophil count were noted (Fig. 1A,B).

Upon discharge, she was on a regimen of oral prednisone (50 mg/day) and mycophenolate mofetil (MMF) (initial dose 1500 mg/day). Because of the patient's neutropenia, with the possibility of azathioprine-induced pancytopenia, MMF was chosen over azathioprine. During follow up, tapering of prednisone was initiated. The patient is currently on her eighth month of follow up and has exhibited a normal neutrophil count and transaminases for three months. She is under a regimen of 10 mg prednisone and 2 g MMF without side effects.

Discussion

AIN is classified as primary (no underlying pathology) and secondary [8]. In primary AIN, autoantibodies act against neutrophils that express human neutrophil antigens (HNAs) [8]. Secondary AIN occurs within the context of systemic diseases. It is usually associated with autoimmune diseases, infections or malignancies (Table 1). In secondary AIN, the correlation between neutropenia and the presence of

Table 1 Etiologies of secondary autoimmune neutropenia

Type of disorder	Etiologies	Disease	Type of disorder	Etiologies	Disease
Acute secondary autoimmune neutropenia	Drugs	Rituximab	Chronic secondary autoimmune neutropenia	Systemic autoimmune diseases	Rheumatoid arthritis and Felty's syndrome
		Fludarabine			Systemic lupus erythematosus
					Sjögren's syndrome
		Propylthiouracil		Systemic sclerosis	
	Infections	HIV			Primary biliary cholangitis
		Parvovirus B19		Hematological malignancies	Large granular lymphocyte leukemia
		<i>Helicobacter pylori</i>			Chronic lymphocytic leukemia
		Influenza			Hodgkin's lymphoma
		Enterovirus		Waldenström macroglobulinemia	
		Viral hepatitis B		Solid tumors	Thymoma
		Viral hepatitis C			Wilm's tumor
		Epstein-Barr virus		Neurological diseases	Multiple sclerosis
Cytomegalovirus		Transplantation	Stem cell		
		Human herpes virus-6		Bone marrow transplantation	
			Kidney		
		Immunodeficiency syndromes	Common variable immunodeficiency		
			Autoimmune lymphoproliferative syndrome		

HNAs is less well established and the target of the autoantibodies remains unknown [8]. These cases often present with other accompanying cytopenias [8].

Many cases of AIH, specifically those with AIH-1, present with atypical pANCA [7,9]. ANCA are antibodies against proteins of cytoplasmic granules or other constituents of neutrophil cytoplasm. Regarding their staining patterns, they have been described as c-ANCA when they label the whole neutrophilic cytoplasm and p-ANCA when they only label the perinuclear cytoplasm [9]. Despite efforts, a predominant target for ANCA in AIH has yet to be identified. These autoantibodies are usually described as “atypical pANCA” [10] and may target an antigen in the nuclear periphery of neutrophils. Therefore, the term “perinuclear antineutrophil nuclear antibodies” (pANNA) might be more suitable [10]. The detection of high titers of ANCA (prevalence rate 40-96%) [9] solidifies the diagnosis of AIH-1, although their role remains obscure [7].

AIN associated with autoimmune liver diseases at the time of diagnosis is very rare. We located only three cases of AIN in the context of AIH [1-3] with positive atypical pANCA. Our case represents a female patient with a flare of AIH-1 on a backdrop of possible chronic unresolved liver inflammation, complicated by severe AIN. In concordance with the existing literature, she was also positive for atypical pANCA [1-3]. The autoimmune origin of her secondary agranulocytosis can be advocated by the absence of alternative causes, the association with the AIH flare and the sustained response to treatment with corticosteroids and MMF [3,9]. It is not yet clear whether the detection of atypical pANCA plays an active pathogenic role in the development of AIN, or whether their presence is a signifier of autoimmune activity [3,7,9].

In conclusion, in our case of severe AIN at presentation of AIH-1, the presence of atypical pANCA implied a strong association with an autoimmune cause of secondary agranulocytosis. Therapy focused on treating the underlying disease could lead to resolution of both pathological

processes. AIH-related agranulocytosis remains a very rare occurrence [1-3], though AIH should be considered as a probable cause of AIN.

References

1. Cuadrado A, Aresti S, Cortés MA, Gómez-Ortega JM, Salcines JR. Autoimmune hepatitis and agranulocytosis. *Dig Liver Dis* 2009;**41**:e14-e16.
2. Shiyovich A, Nesher L, Smolyakov R, Yermiyahu T, Shubinsky G, Perez-Avraham G. Agranulocytosis at first presentation of autoimmune hepatitis type-1. *Am J Med Sci* 2009;**337**:466-469.
3. Wehbe AM, Johannsson B, Raife TJ, et al. Severe autoimmune neutropenia associated with acute autoimmune hepatitis. *Int J Hematol* 2010;**91**:673-678.
4. Alvarez F, Berg PA, Bianchi FB, et al. International Autoimmune Hepatitis Group Report: Review of criteria for diagnosis of autoimmune hepatitis. *J Hepatol* 1999;**31**:929-938.
5. Hennes EM, Zeniya M, Czaja AJ, et al. Simplified diagnostic criteria for autoimmune hepatitis. *Hepatology* 2008;**48**:169-176.
6. Muratori P, Lenzi M, Cassani F, Lalanne C, Muratori L. Diagnostic approach to autoimmune hepatitis. *Expert Rev Clin Immunol* 2017;**13**:769-779.
7. Zachou K, Rigopoulou E, Dalekos GN. Autoantibodies and autoantigens in autoimmune hepatitis: Important tools in clinical practice and to study pathogenesis of the disease. *J Autoimmune Dis* 2004;**1**:2.
8. Capsoni F, Sarzi-Puttini P, Zanella A. Primary and secondary autoimmune neutropenia. *Arthritis Res Ther* 2005;**7**:208-214.
9. Roozendaal C, de Jong MA, van den Berg AP, van Wijk RT, Limburg PC, Kallenberg CG. Clinical significance of antineutrophil cytoplasmic antibodies (ANCA) in autoimmune liver diseases. *J Hepatol* 2000;**32**:734-741.
10. Terjung B, Worman HJ, Herzog V, Sauerbruch T, Spengler U. Differentiation of antineutrophil nuclear antibodies in inflammatory bowel and autoimmune liver diseases from antineutrophil cytoplasmic antibodies (p-ANCA) using immunofluorescence microscopy. *Clin Exp Immunol* 2001;**126**:37-46.