

Supplementary Materials of the Manuscript:

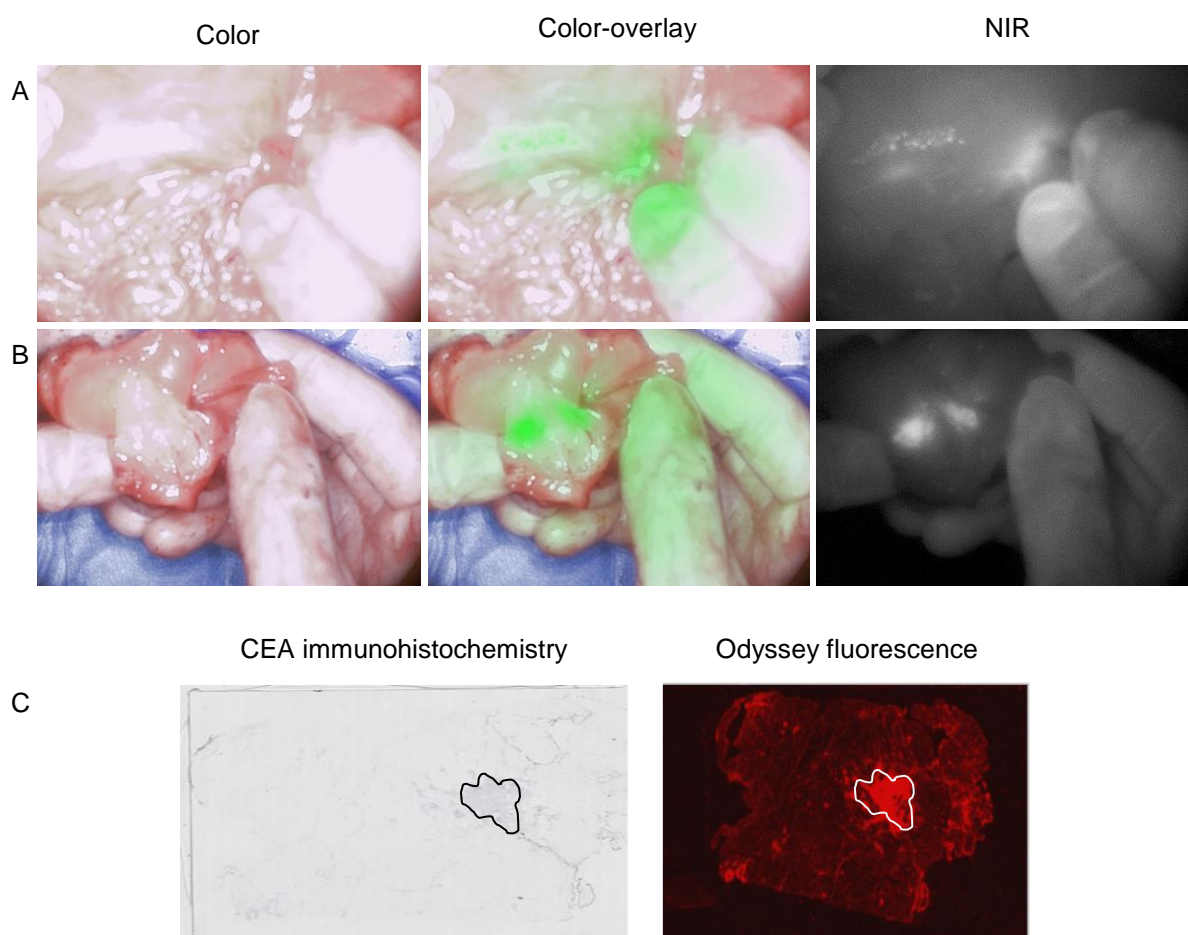
**“Dose-finding study of a CEA-targeting agent, SGM-101, for intraoperative fluorescence imaging of colorectal carcinoma”**

de Valk et al

**Supplementary Table 1: Overview of (serious) adverse events**

| <u>Cohort</u>          | <u>System organ class</u>                            | <u>Symptom</u>                          | <u>Severity</u> | <u>SAE</u> | <u>Relationship SGM-101</u> | <u>Occurrence</u> |
|------------------------|--|---|-----------------|------------|-----------------------------|-------------------|
| <b>5.0 mg SGM-101</b>  |  |   |                 |            |                             |                   |
| Patient 1              | Skin and subcutaneous tissue disorders               | Scar pain                               | Mild            | No         | Unrelated                   | Single occasion   |
|                        | Gastrointestinal disorders                           | Ileus paralytic                         | Mild            | No         | Unrelated                   | Single occasion   |
|                        | General disorders and administration site conditions | Pyrexia                                 | Mild            | No         | Unrelated                   | Single occasion   |
|                        | Gastrointestinal disorders                           | Proctalgia                              | Mild            | No         | Unrelated                   | Single occasion   |
| Patient 2              | Gastrointestinal disorders                           | Nausea                                  | Mild            | No         | Unrelated                   | Single occasion   |
| Patient 3              | Metabolism and nutrition disorders                   | Dehydration                             | Mild            | No         | Unrelated                   | Single occasion   |
| Patient 4              | Infections and infestations                          | Urinary tract infection                 | Mild            | No         | Unrelated                   | Single occasion   |
|                        | Injury, poisoning and procedural complications       | Scratch                                 | Mild            | No         | Unrelated                   | Single occasion   |
|                        | Gastrointestinal disorders                           | Nausea                                  | Mild            | No         | Unrelated                   | Intermittent      |
|                        | Vascular disorders                                   | Scrotal hematoma                        | Mild            | No         | Unrelated                   | Single occasion   |
|                        | Gastrointestinal disorders                           | Ileus paralytic                         | Moderate        | Yes        | Unrelated                   | Single occasion   |
|                        | Injury, poisoning and procedural complications       | Renal injury                            | Moderate        | Yes        | Unrelated                   | Single occasion   |
| <b>7.5 mg SGM-101</b>  |  |   |                 |            |                             |                   |
| Patient 6              | Skin and subcutaneous tissue disorders               | Rash                                    | Mild            | No         | Possible                    | Intermittent      |
|                        | Vascular disorders                                   | Systemic inflammatory response syndrome | Moderate        | No         | Unrelated                   | Single occasion   |
|                        | Vascular disorders                                   | Orthostatic hypotension                 | Mild            | No         | Unrelated                   | Intermittent      |
| Patient 7              | Gastrointestinal disorders                           | Nausea                                  | Mild            | No         | Unrelated                   | Single occasion   |
| Patient 5              | General disorders and administration site conditions | Flank pain                              | Mild            | No         | Unrelated                   | Single occasion   |
| <b>10.0 mg SGM-101</b> |  |   |                 |            |                             |                   |
| Patient 9              | Nervous system disorders                             | Headache                                | Mild            | No         | Possible                    | Single occasion   |
|                        | Injury, poisoning and procedural complications       | Phlebitis                               | Mild            | No         | Unrelated                   | Intermittent      |
|                        | Gastrointestinal disorders                           | Nausea                                  | Mild            | No         | Unrelated                   | Single occasion   |
| Patient 10             | Gastrointestinal disorders                           | Abdominal pain                          | mild            | No         | Possible                    | Intermittent      |
|                        | Musculoskeletal and connective tissue disorders      | Muscle tightness                        | Mild            | No         | Unrelated                   | Single occasion   |
| Patient 11             | Musculoskeletal and connective tissue disorders      | Redness finger                          | Mild            | No         | Unlikely                    | Single occasion   |
|                        | Cardiac disorders                                    | Atrial fibrillation                     | Mild            | No         | Unrelated                   | Single occasion   |
|                        | Skin and subcutaneous tissue disorders               | Decubitus ulcer                         | Mild            | No         | Unrelated                   | Single occasion   |
|                        | Infections and infestations                          | Wound infection                         | Mild            | No         | Unrelated                   | Single occasion   |
| Patient 27             | Infections and infestations                          | Pneumonia                               | Mild            | No         | Unrelated                   | Single occasion   |
|                        | Nervous system disorders                             | Neuropathy peripheral                   | Mild            | No         | Unrelated                   | Single occasion   |
| Patient 13             | Infections and infestations                          | Urinary tract infection                 | Mild            | No         | Unrelated                   | Single occasion   |
| Patient 14             | Renal and urinary disorders                          | Pyelonephritis                          | Moderate        | Yes        | Unrelated                   | Single occasion   |
| Patient 16             | Nervous system disorders                             | Headache                                | Mild            | No         | Possible                    | Single occasion   |
| Patient 20             | Nervous system disorders                             | Headache                                | Mild            | No         | Possible                    | Single occasion   |
| Patient 23             | Nervous system disorders                             | Peripheral sensorimotor neuropathy      | Mild            | No         | Unrelated                   | Single occasion   |
| Patient 25             | Nervous system disorders                             | Neuropathy peripheral                   | Mild            | No         | Unrelated                   | Persistent        |
| <b>12.5 mg SGM-101</b> |  |   |                 |            |                             |                   |
| Patient 29             | Hepatobiliary disorders                              | Hepatic necrosis                        | Moderate        | Yes        | Unrelated                   | Single occasion   |
| Patient 28             | Infections and infestations                          | Abdominal abscess                       | Mild            | No         | Unrelated                   | Single occasion   |
| <b>15.0 mg SGM-101</b> |  |   |                 |            |                             |                   |
| Patient 33             | Infections and infestations                          | Pneumonia                               | Moderate        | No         | Unrelated                   | Single occasion   |
|                        | Injury, poisoning and procedural complications       | Gastroparesis postoperative             | Mild            | No         | Unrelated                   | Single occasion   |
| Patient 36             | Nervous system disorders                             | Cerebral hemorrhage                     | Severe          | Yes        | Unlikely                    | Persistent        |
| Patient 37             | Injury, poisoning and procedural complications       | Postoperative ileus                     | Moderate        | No         | Unrelated                   | Single occasion   |
|                        | Infections and infestations                          | Postoperative abscess                   | Moderate        | No         | Unrelated                   | Single occasion   |

**Supplementary Figure 1: Recurrent tumour against peritoneum (false positive).** Figure A shows the intraoperative images, figure B shows the back table images and figure C shows the CEA staining and fluorescence correlation with the Odyssey on microscopic level. The presence of low and weak CEA expression in the lesion plausibly explains the (false positive) fluorescence during surgery.



Supplementary Table 2: Overview of excised lesions

| Treatment       | PID                             | Resected lesion                | Clinically suspect | Fluorescent | TBR in vivo | TBR ex vivo | Pathology   | Diagnosis                                     | Conclusion     |
|-----------------|---------------------------------|--------------------------------|--------------------|-------------|-------------|-------------|---|---|----------------|
| 5 mg SGM-101    | 1                               | Tumor rectum                   | yes                | yes         | !           | 1.8         | Malignant   | Adenocarcinoma                                | True positive  |
|                 | 2                               | Tumor rectum                   | yes                | yes         | 1.5         |             | Malignant   | Adenocarcinoma                                | True positive  |
|                 | 3                               | Tumor rectum                   | no                 | no          |             |             | Benign  | No restumor: complete response                | True negative  |
|                 |                                 | Re-resection bladder wall      | no                 | yes         | 1.6         |             | Benign  | No tumor cells                                | False positive |
| 7.5 mg SGM-101  | 4                               | Tumor                          | yes                | yes         | 1.4         |             | Malignant   | Mucinous adenocarcinoma                       | True positive  |
|                 | 5                               | Tumor                          | yes                | yes         | 1.4         |             | Malignant   | Intestinal adenocarcinoma                     | True positive  |
|                 |                                 | Biopt resection plane          | no                 | yes         | 1.3         |             | Benign  | No tumor cells                                | False positive |
|                 |                                 | Biopt resection plane          | no                 | yes         | 1.3         |             | Benign  | No tumor cells                                | False positive |
|                 |                                 | Omental lesion                 | no                 | no          |             |             | Benign  | Sinus histiocytosis                           | True negative  |
|                 |                                 | Lymph node                     | yes                | yes         | !           | 1.8         | Benign  | Sinus histiocytosis                           | False positive |
|                 | 6                               | Tumor sigmoid                  | yes                | yes         | 2.1         |             | Malignant   | Adenocarcinoma                                | True positive  |
|                 |                                 | Lesion liver segment 2/3       | yes                | yes         | 1.5         |             | Malignant   | Adenocarcinoma                                | True positive  |
|                 | Lesion liver 4B                 | yes                            | yes                | 1.7         |             | Malignant   | Adenocarcinoma  | True positive                                 |                |
|                 | Lesion liver 6                  | yes                            | yes                | 1.4         |             | Malignant   | Adenocarcinoma  | True positive                                 |                |
| 10 mg SGM-101   | 7                               | Tumor rectum                   | no                 | no          |             |             | Benign  | No restumor: complete response                | True negative  |
|                 | 8                               | Tumor rectum                   | yes                | yes         | !           | 5.0         | Malignant   | Adenocarcinoma                                | True positive  |
|                 |                                 | Lymph node                     | yes                | yes         | !           | 1.9         | Malignant   | Adenocarcinoma                                | True positive  |
|                 | 9                               | Tumor colon                    | yes                | yes         | 1.9         |             | Malignant   | Adenocarcinoma                                | True positive  |
|                 |                                 | Ingrowth omental               | yes                | yes         | 2.2         |             | Malignant   | Adenocarcinoma                                | True positive  |
|                 |                                 | Lymph node                     | yes                | no          |             |             | Malignant   | Adenocarcinoma                                | False negative |
|                 | 10                              | Biopt lesion peritoneum        | no                 | yes         | 1.7         |             | Benign  | Ink spot; no tumor cells                      | False positive |
|                 | 11                              | Tumor sigmoid                  | yes                | yes         | 1.8         |             | Malignant   | Adenocarcinoma                                | True positive  |
|                 | 12                              | Recurrence anastomosis         | yes                | yes         | 1.7         |             | Malignant   | Adenocarcinoma                                | True positive  |
|                 |                                 | Lesion around ureter (LN)      | no                 | yes         | 1.9         |             | Malignant   | Adenocarcinoma                                | True positive  |
|                 |                                 | Lesion piriformis              | no                 | no          |             |             | Benign  | No tumor cells                                | True negative  |
|                 |                                 | Lesion left ureter             | yes                | yes         | 1.6         |             | Benign  | Collagen tissue                               | False positive |
|                 | 13                              | Prostate, recurrence spot      | yes                | yes         | !           | 1.9         | Malignant   | Adenocarcinoma                                | True positive  |
|                 |                                 | Lesion adhesion small bowel    | yes                | no          |             |             | Benign  | Fibrotic collagen tissue                      | True negative  |
|                 | 14                              | Lesion anastomosis, recurrence | yes                | yes         | 1.9         |             | Malignant   | Intestinal adenocarcinoma                     | True positive  |
|                 |                                 | Lesion peritoneum small pelvis | yes                | no          |             |             | Benign  | No tumor cells                                | True negative  |
|                 |                                 | Second lesion                  | no                 | yes         | !           | 2.1         | Malignant   | Intestinal adenocarcinoma                     | True positive  |
|                 | 15                              | Tumor                          | yes                | yes         | !           | 1.6         | Malignant   | Adenocarcinoma                                | True positive  |
|                 |                                 | LN                             | yes                | no          |             |             | Benign  | No tumor cells                                | True negative  |
|                 |                                 | Lesion lateral pelvic wall     | no                 | yes         | !           | 1.4         | Malignant   | Adenocarcinoma                                | True positive  |
|                 |                                 | Lesion small bowel             | yes                | yes         | 1.4         |             | Benign  | No tumor cells                                | False positive |
|                 | 16                              | Tumor rectum                   | yes                | yes         | 2.0         |             | Malignant   | Low grade intestinale adenocarcinoma          | True positive  |
|                 | 17                              | Tumor                          | yes                | yes         | !           | 2.2         | Malignant   | Adenocarcinoma                                | True positive  |
|                 |                                 | LN                             | no                 | yes         | !           | 2.2         | Benign  | No tumor cells                                | False positive |
|                 |                                 | LN AMI                         | no                 | no          |             |             | Benign  | No tumor cells                                | True negative  |
|                 |                                 | Re-excision caudal left        | no                 | yes         | 1.8         |             | Malignant   | Adenocarcinoma                                | True positive  |
|                 |                                 | Re-excision cranial right      | no                 | yes         | 1.8         |             | Malignant   | Adenocarcinoma                                | True positive  |
|                 | 18                              | Tumor rectum                   | no                 | no          |             |             | Benign  | No restumor: complete response                | True negative  |
|                 |                                 | Tumor ingrowth vagina          | no                 | no          |             |             | Benign  | No restumor                                   | True negative  |
|                 | 19                              | Tumor recurrence spot          | yes                | yes         | 1.5         |             | Benign  | Tissue with fibrosis                          | False positive |
|                 | 20                              | Sacrum, recurrence spot        | yes                | yes         | !           | 1.7         | Malignant   | Sarcomatous differentiated carcinoma          | True positive  |
|                 |                                 | Resection plane prostate       | no                 | no          |             |             | Benign  | No tumor cells                                | True negative  |
|                 | Tissue between bladder + sacrum | yes                            | yes                | !           | 1.8         | Malignant   | Sarcomatous differentiated carcinoma                  | True positive                                 |                |
| 21              | Tumor 1                         | yes                            | yes                | !           | 3.0         | Malignant   | Adenocarcinoma  | True positive                                 |                |
|                 | Tumor 2                         | yes                            | yes                | !           | 1.8         | Malignant   | Adenocarcinoma  | True positive                                 |                |
|                 | LN                              | no                             | no                 |             |             | Benign      | No tumor cells  | True negative                                 |                |
|                 | Lesion lateral pelvic wall      | no                             | yes                | !           | 1.6         | Malignant   | Adenocarcinoma  | True positive                                 |                |
|                 | Re-excision                     | no                             | yes                | !           | 1.5         | Malignant   | Limited (border) adenocarcinoma                       | True positive                                 |                |
| 22              | Tumor rectum                    | yes                            | yes                | !           | 1.5         | Malignant   | Adenocarcinoma  | True positive                                 |                |
|                 | Re-excision dorsolateral right  | no                             | yes                | !           | 1.4         | Benign      | Fat and fibrotic connective tissue, bloodvessels      | False positive                                |                |
|                 | Re-excision presacral           | yes                            | yes                | !           | 1.2         | Benign      | Fat and fibrotic connective tissue, bloodvessels      | False positive                                |                |
| 23              | Tumor rectum                    | yes                            | yes                | !           | 1.5         | Malignant   | Adenocarcinoma  | True positive                                 |                |
|                 | Re-excision tissue              | no                             | yes                | !           | 1.3         | Benign      | Fat and connective tissue, nerve tissue               | False positive                                |                |
| 24              | Recurrence retroperitoneum      | yes                            | yes                | 1.5         | 1.6         | Benign      | Fat tissue with fibrosis, macrophages, calcifications | False positive                                |                |
| 25              | Tumor rectum                    | yes                            | no                 |             |             | Benign      | No restumor: complete response                        | True negative                                 |                |
| 26              | Tumor colon                     | yes                            | no                 |             |             | Benign      | No restumor: complete response                        | True negative                                 |                |
|                 | Lesion anastomosis              | no                             | no                 |             |             | Benign      | No tumor cells  | True negative                                 |                |
|                 | Biopt presacral left            | no                             | no                 |             |             | Benign      | No tumor cells  | True negative                                 |                |
|                 | Biopt presacral left            | no                             | no                 |             |             | Benign      | No tumor cells  | True negative                                 |                |
|                 | Biopt presacral                 | no                             | no                 |             |             | Benign      | No tumor cells  | True negative                                 |                |
| 27              | Tumor rectum                    | yes                            | yes                | !           | 1.4         | Malignant   | Adenocarcinoma  | True positive                                 |                |
|                 | Biopt presacral                 | no                             | yes                | !           | 1.2         | Benign      | Fat and connective tissue                             | False positive                                |                |
|                 | Biopt presacral left            | no                             | no                 |             |             | Benign      | No tumor cells  | True negative                                 |                |
|                 | Biopt presacral right           | no                             | no                 |             |             | Benign      | No tumor cells  | True negative                                 |                |
| 12.5 mg SGM-101 | 28                              | Tumor rectum                   | yes                | yes         | !           | 1.8         | Malignant   | Adenocarcinoma                                | True positive  |
|                 |                                 | Vasa ovarica                   | no                 | yes         | !           | 1.3         | Benign  | Ovary stroma, connective tissue, bloodvessels | False positive |
|                 | 29                              | Tumor colon                    | yes                | yes         | 2.0         | 1.5         | Malignant   | Adenocarcinoma                                | True positive  |
|                 |                                 | Lesion liver                   | yes                | yes         | 1.3         |             | Malignant   | Adenocarcinoma                                | True positive  |
|                 | 30                              | Tumor rectum                   | yes                | yes         | !           | 1.4         | Malignant   | Adenocarcinoma                                | True positive  |
|                 |                                 | Lymph node                     | yes                | yes         | 1.4         | 1.5         | Malignant   | Adenocarcinoma                                | True positive  |
|                 |                                 | Left vesicula seminalis        | no                 | yes         | 1.3         | 1.8         | Benign  | Vesicula seminalis                            | False positive |
|                 | 31                              | Tumor rectum                   | yes                | no          |             |             | Benign  | No restumor: complete response                | True negative  |
|                 | Left ovarium                    | no                             | yes                | 1.2         | 1.5         | Benign      | Ovary   | False positive                                |                |
| 32              | Tumor rectum                    | yes                            | yes                | !           | 1.8         | Malignant   | Mucineus adenocarcinoma                               | True positive                                 |                |
|                 | Lesion lateral pelvic wall      | no                             | yes                | !           | 1.6         | Malignant   | Mucineus adenocarcinoma                               | True positive                                 |                |
|                 | Re-excision S4                  | no                             | no                 |             |             | Benign      | Fibrosis, fat tissue, connective tissue               | True negative                                 |                |
|                 | Re-excision S3                  | no                             | no                 |             |             | Benign      | Fibrosis, fat tissue, connective tissue               | True negative                                 |                |
|                 | Biopt tumorwall left side       | yes                            | no                 |             |             | Malignant   | Mucineus adenocarcinoma                               | False negative                                |                |
| 15 mg SGM-101   | 33                              | Tumor rectum                   | yes                | yes         | !           | 1.1         | Malignant   | Adenocarcinoma                                | True positive  |
|                 |                                 | Lesion (possible LN)           | yes                | yes         | !           | 1.5         | Benign  | Vesicula seminalis                            | False positive |
|                 | 34                              | Tumor rectum                   | yes                | yes         | 1.1         | 1.3         | Malignant   | Adenocarcinoma                                | True positive  |
|                 |                                 | Biopt dorsolateral right       | no                 | no          |             |             | Benign  | No tumor cells                                | True negative  |
|                 |                                 | Biopt lateral pelvis wall      | yes                | yes         | 1.5         |             | Benign  | Connective tissue                             | False positive |
|                 |                                 | Biopt left vesicula seminalis  | no                 | no          |             |             | Benign  | No tumor cells                                | True negative  |
|                 | 35                              | Tumor rectum                   | yes                | yes         | !           | 1.9         | Malignant   | Adenocarcinoma                                | True positive  |
|                 |                                 | Re-resection pelvic floor      | yes                | yes         | !           | 1.5         | Malignant   | Adenocarcinoma                                | True positive  |
|                 | 36                              | Tumor rectum                   | yes                | no          |             |             | Benign  | No restumor: complete response                | True negative  |
|                 |                                 | lymph node packet 1            | yes                | yes         | !           | 1.4         | Malignant   | Macrometastasis                               | True positive  |
|                 | lymph node packet 2             | yes                            | yes                | !           | 1.5         | Malignant   | Micrometastasis                                       | True positive                                 |                |
|                 | Denonwillien                    | no                             | yes                | !           | 1.2         | Benign      | Mucine deposit; no tumor cells                        | False positive                                |                |
| 37              | Tumor rectum                    | yes                            | yes                | !           | 1.6         | Malignant   | Vital tumor cells                                     | True positive                                 |                |
|                 | Biopt pelvic floor              | no                             | yes                | 1.8         |             | Benign      | Connective tissue                                     | False positive                                |                |
|                 | Biopt lateral pelvic wall       | yes                            | yes                | 2.0         | 1.8         | Benign      | Connective tissue                                     | False positive                                |                |

PID: patient ID; TBR: tumor-to-background ratio  
 ! no in vivo fluorescence measured

**Supplementary Figure 2: Ex vivo (back table) tumor-to-background ratio (TBR) per****dose level.** The figure displays the median and range of the ex vivo TBRs. The mean ex

vivo TBRs for the 5 mg, 7.5 mg, 10 mg, 12.5 mg and 15 mg dose levels are 1.8, 3.5, 1.8, 1.6

and 1.5, respectively. Note: the dosing-surgery interval time varies within the different dose

levels.

