
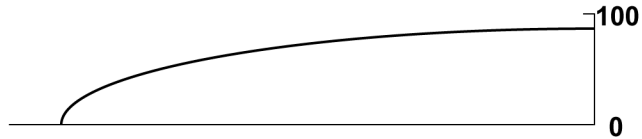


GRMD


Increase in Q/R ratio in leads II, III and aVF



Hyperechoic lesion in posterior wall by echocardiography

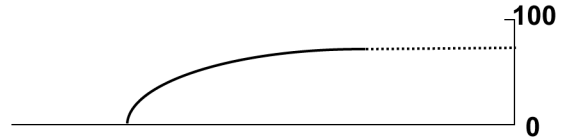



Fibrotic change in posterior wall by pathology



2 4 6 8 10 12 14 16 18 20 22 24 mo

CXMD_J



2 4 6 8 10 12 14 16 18 20 mo