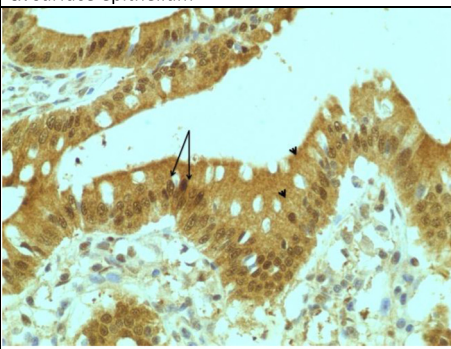
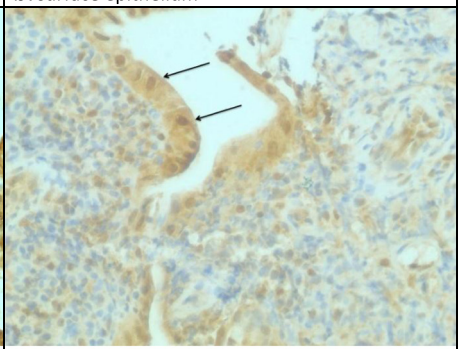
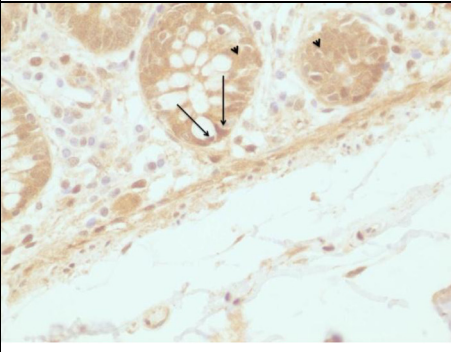
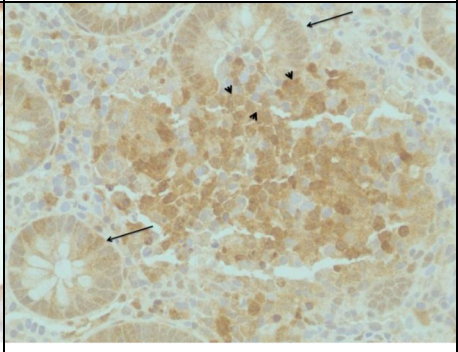
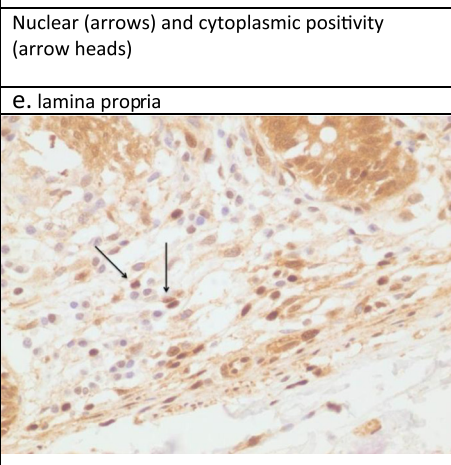
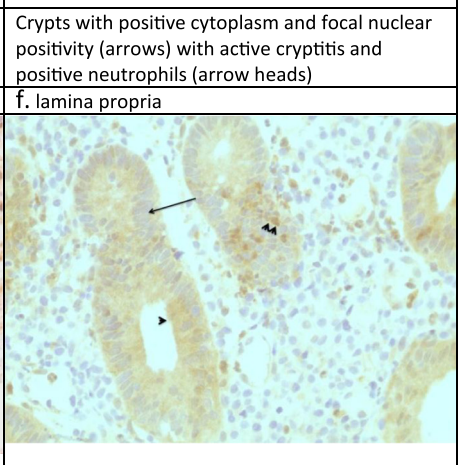


| Normal tissue  | UC tissue   |
|--|---|
| <p><b>a. surface epithelium</b></p>  <p>Strong nuclear (arrows) and cytoplasmic positivity (arrow heads)</p> | <p><b>b. surface epithelium</b></p>  <p>The surface epithelium retains nuclear and weak cytoplasmic positivity (arrows)</p>  |
| <p><b>c. crypts</b></p>  <p>Nuclear (arrows) and cytoplasmic positivity (arrow heads)</p>                   | <p><b>d. crypts</b></p>  <p>Crypts with positive cytoplasm and focal nuclear positivity (arrows) with active cryptitis and positive neutrophils (arrow heads)</p> |
| <p><b>e. lamina propria</b></p>  <p>Scattered positive nuclei (arrows)</p>                                 | <p><b>f. lamina propria</b></p>  <p>Crypts with negative nuclei (arrow), positive cytoplasm (arrow head) and positive neutrophils (arrow heads)</p>              |