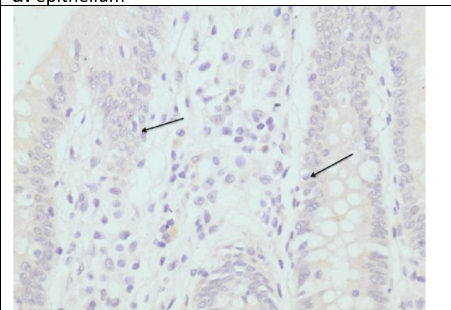
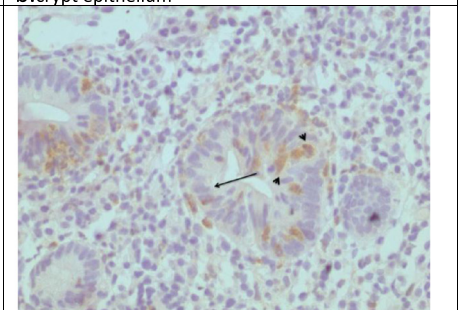
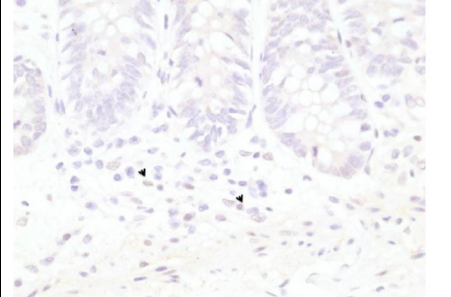
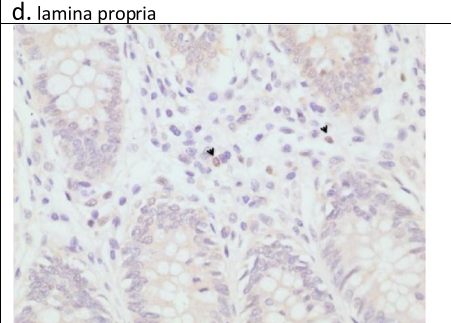



| | |
|------------------------------------------------------------------------------------------------------------------------------|-----------------------------------------------------------------------------------------------------------------------------------|
| Normal tissue | UC tissue |
| <p>a. epithelium</p>  | <p>b. crypt epithelium</p>  |
| <p>Negative normal surface epithelium (arrows)</p> | <p>Negative epithelium (arrows) and positive neutrophils (arrow heads)</p> |
| <p>c. crypts</p>  | |
| <p>Negative nuclei and cytoplasm and sparse positive nuclei in the lamina propria of normal colonic mucosa (arrow heads)</p> | |
| <p>d. lamina propria</p>  | <p>e. purulent material from ulcer</p>  |
| <p>Scattered positive nuclei of mononuclear cells in the lamina propria of normal mucosa (arrow heads)</p> | <p>Negative neutrophils in purulent material (arrow heads) positive nuclei of mononuclear cells (arrows)</p> |