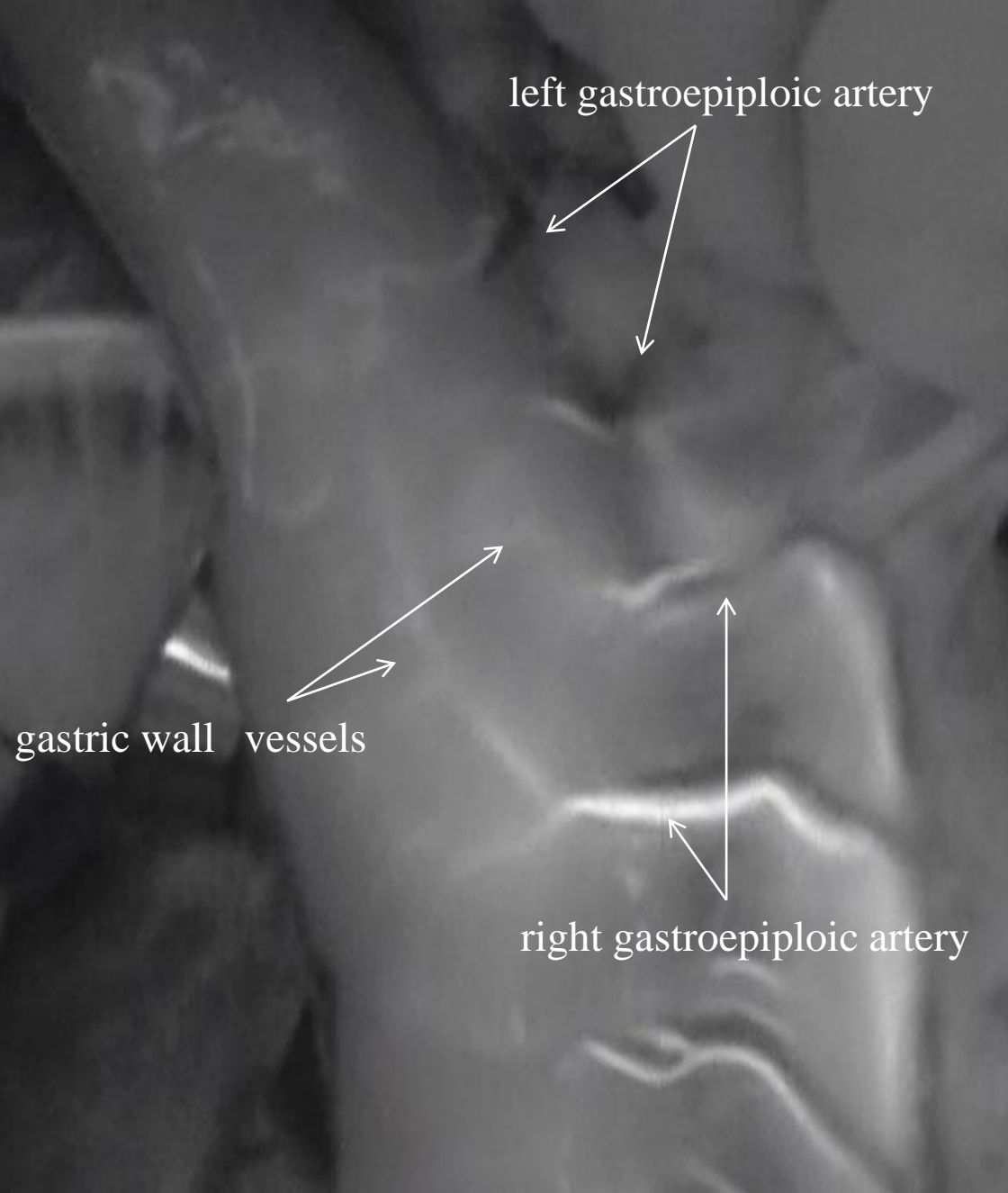


left gastroepiploic artery



gastric wall vessels



right gastroepiploic artery

