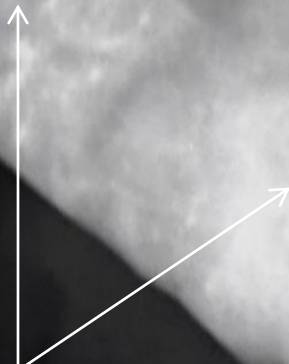


short gastric artery



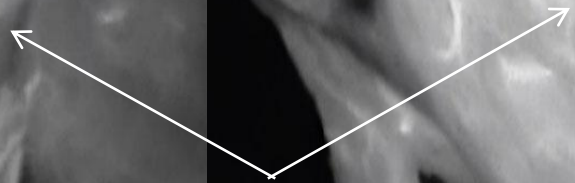
gastric wall vessels



splenic hiatal vessels



left gastroepiploic artery



short gastric artery



gastric wall vessels

