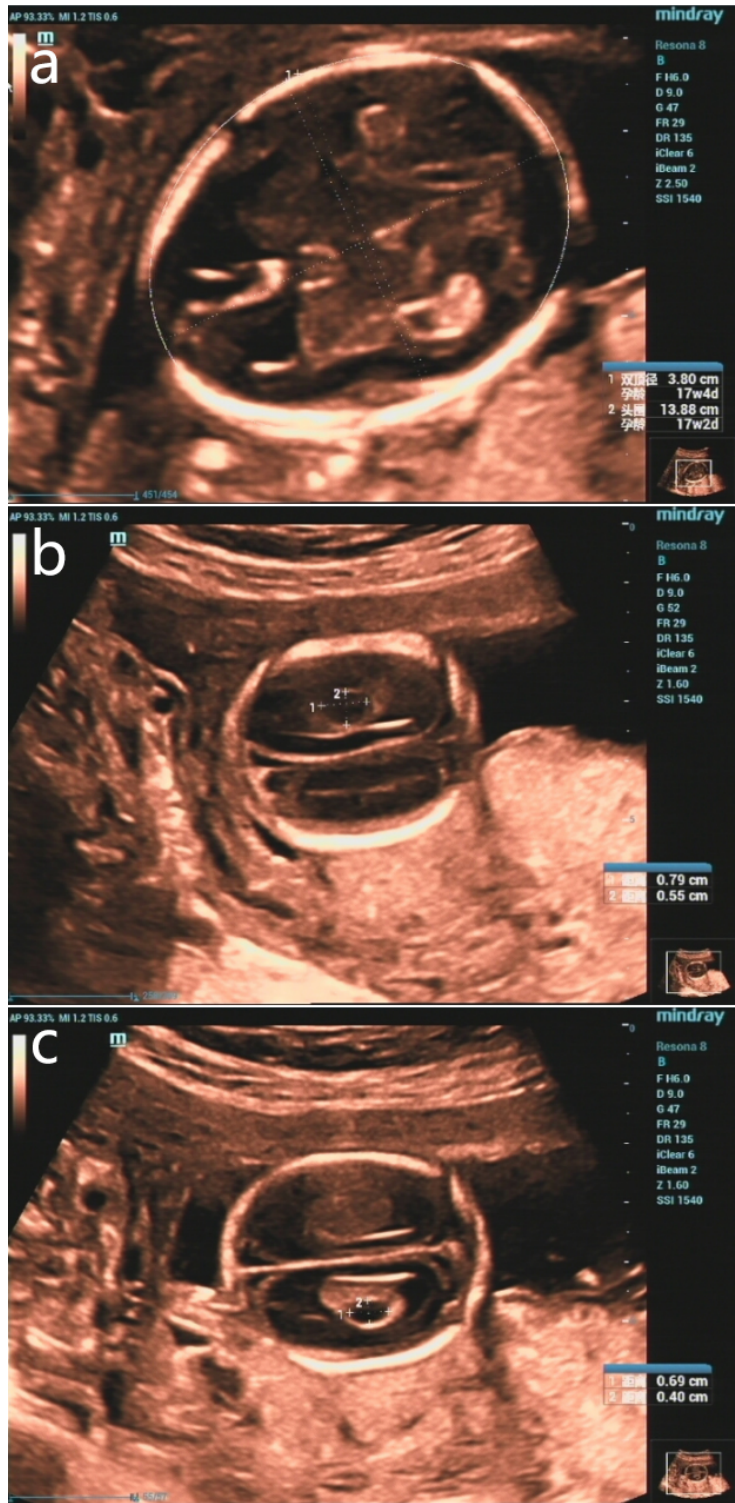


Supplementary file



2
 Figure S1: Ultrasound images of the fetus (17 2/7 weeks of gestation). (a) fetal skull measurement data; (b) choroid plexus cysts (CPC) in the lateral ventricles, 0.79 x 0.55 mm on the right; (c) choroid plexus cysts (CPC) in the cateral ventricles, 6.9 x 4.0 mm on the left.