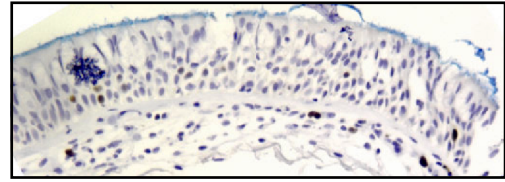
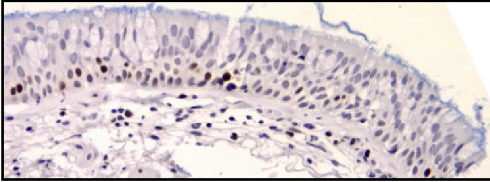
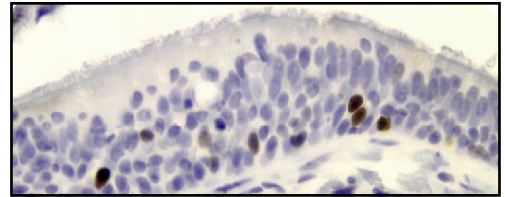
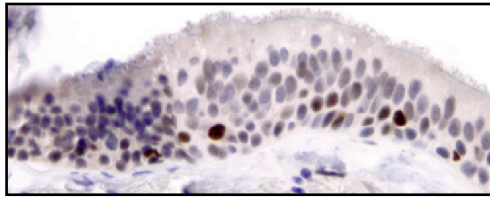


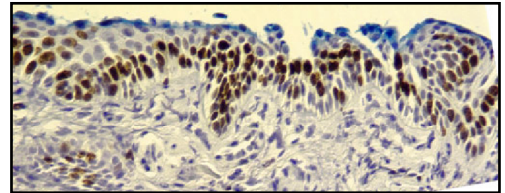
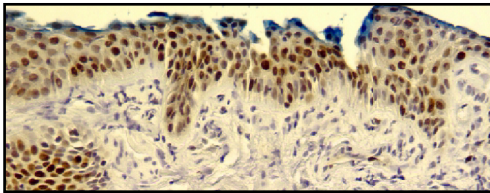
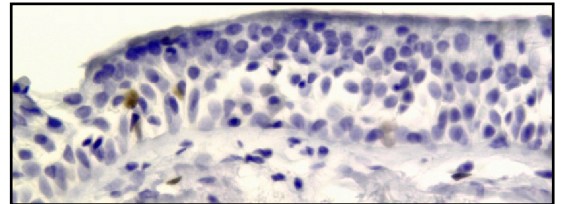
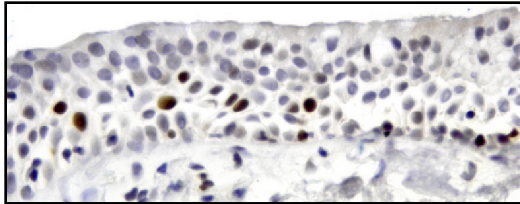
Anti-HsMCM2

Anti-Ki-67

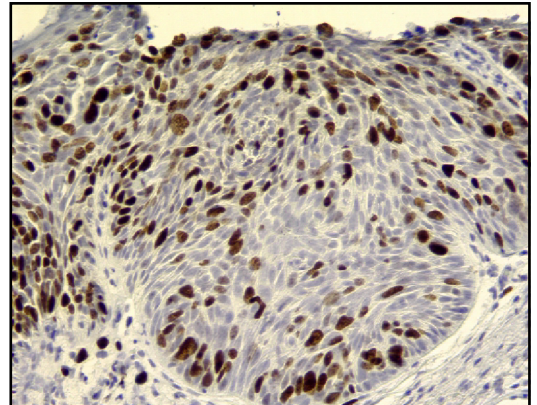
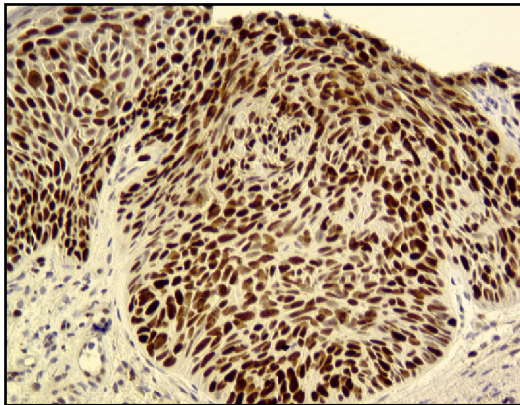
Normal  
Bronchial  
Mucosa



Meta-  
plasia



High  
Grade  
Dysplasia



Carcinoma  
in situ

