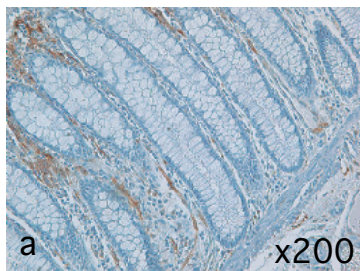
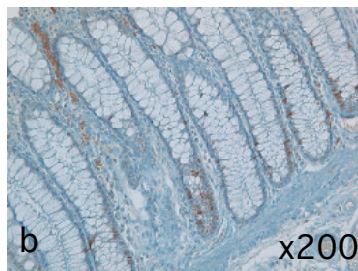


Normal
epithelium

Fascin

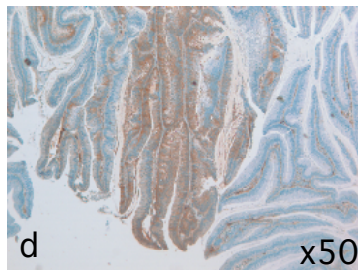
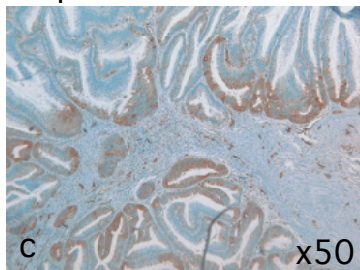


Ki67

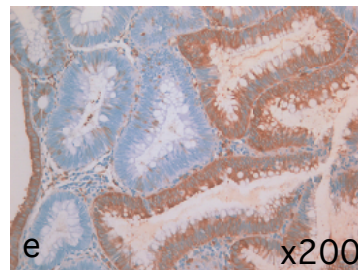


Adenomas

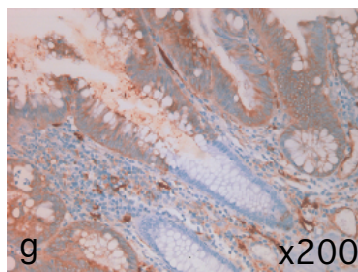
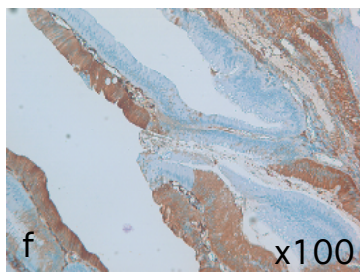
Sporadic adenoma



FAP



Fascin



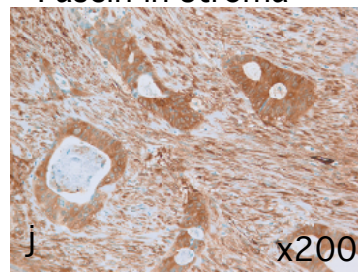
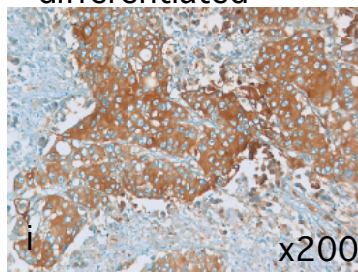
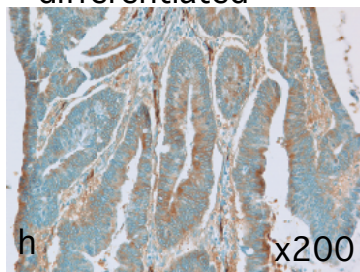
Carcinomas

Moderately
differentiated

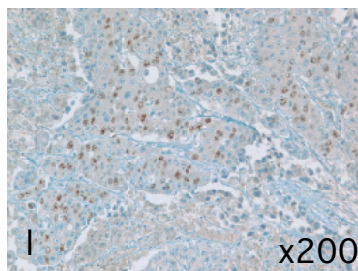
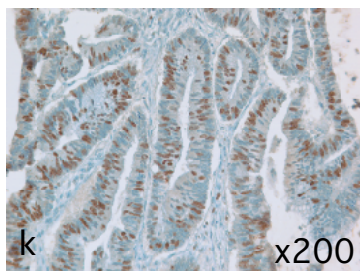
Poorly
differentiated

Fascin in stroma

Fascin



Ki67

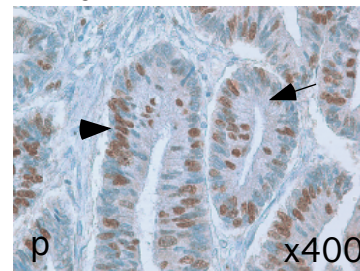
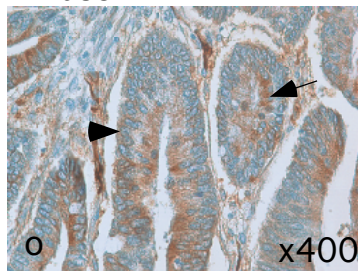
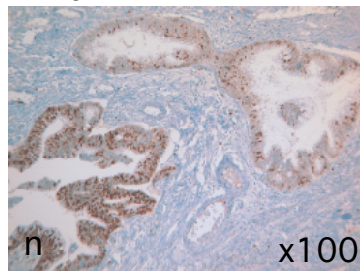
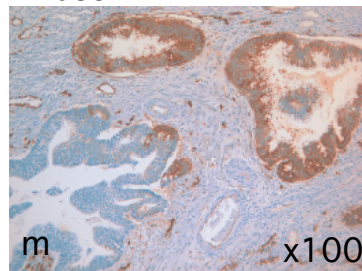


Fascin

Ki67

Fascin

Ki67



Adenoma

Carcinoma