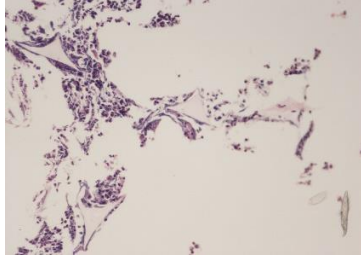
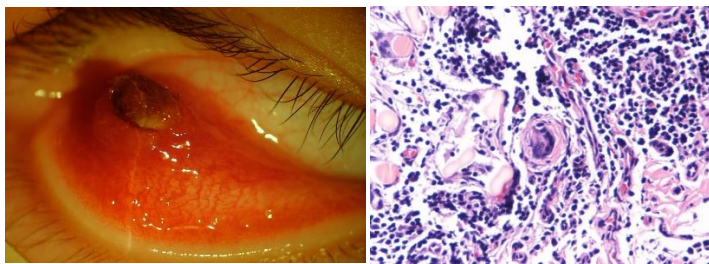


Clinical photographs of 18 patients with synthetic fiber conjunctival granuloma

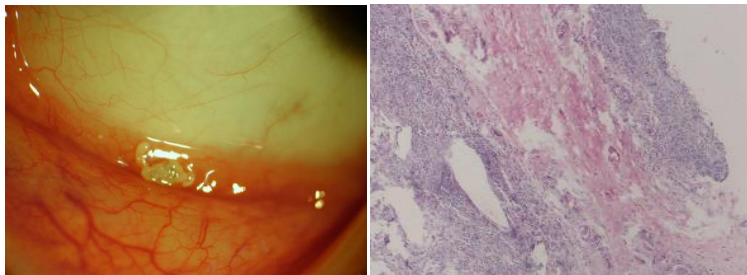
Case 1



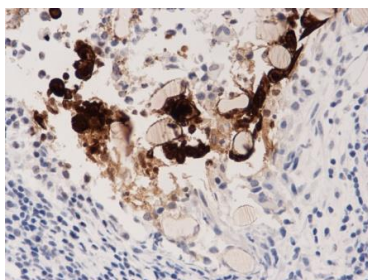
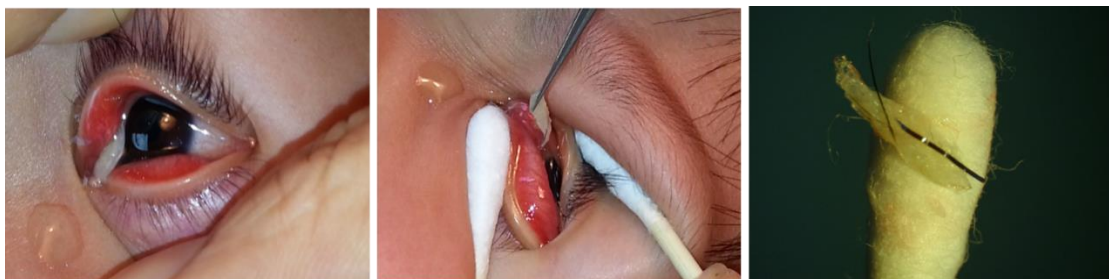
Case 2



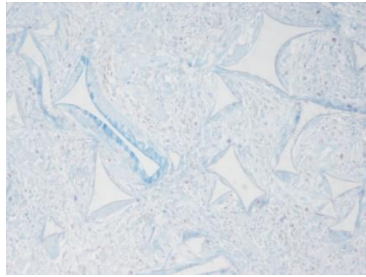
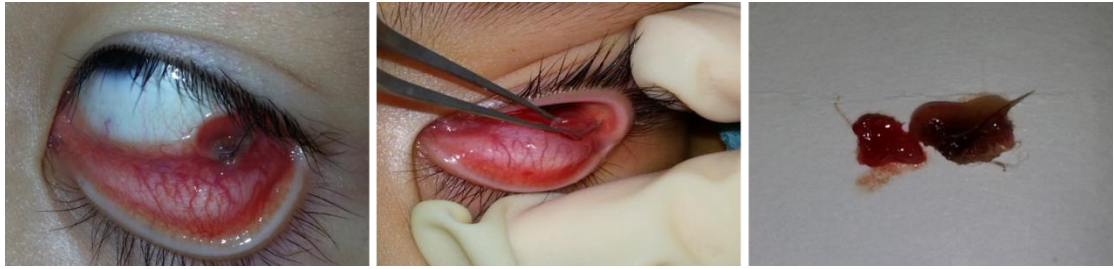Case 3



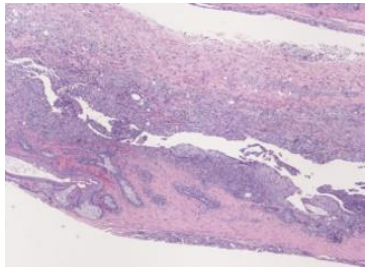
Case 4



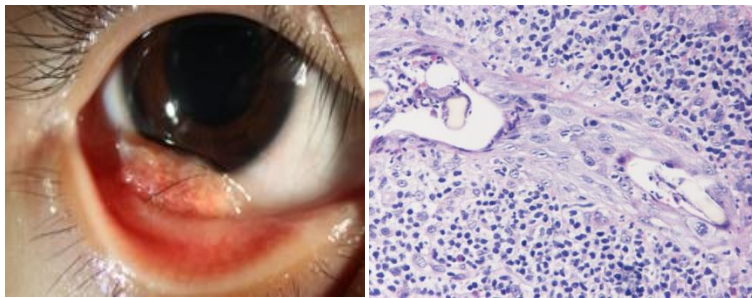
Case 5



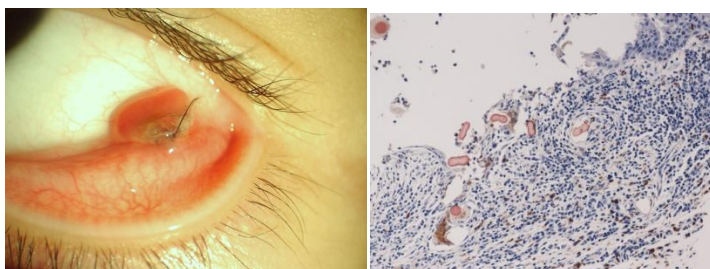
Case 6



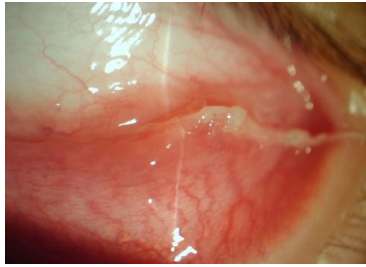
Case 7



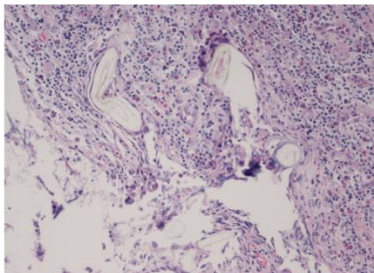
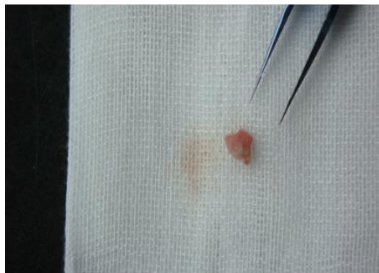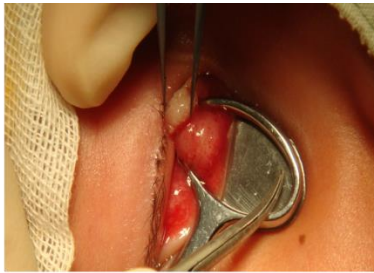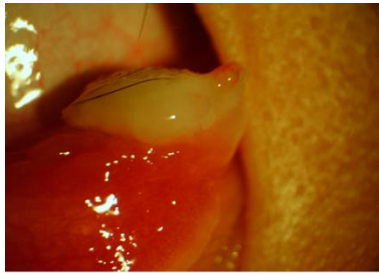Case 8



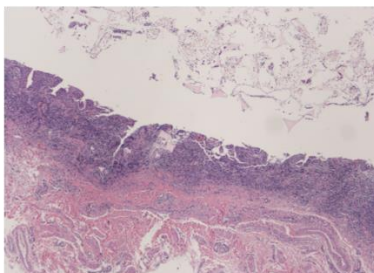
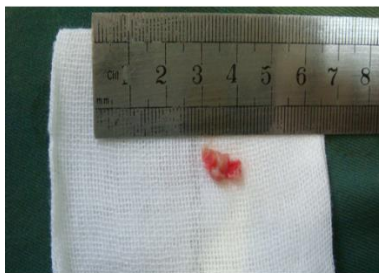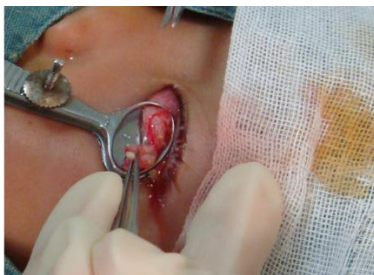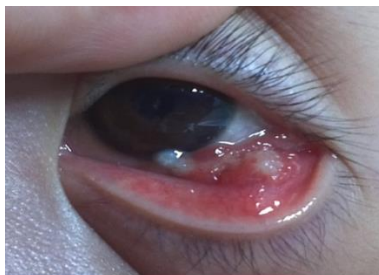Case 9



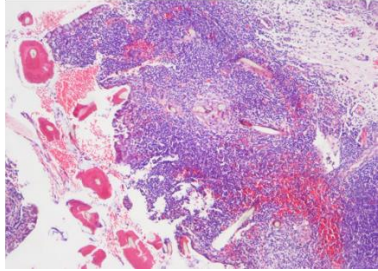
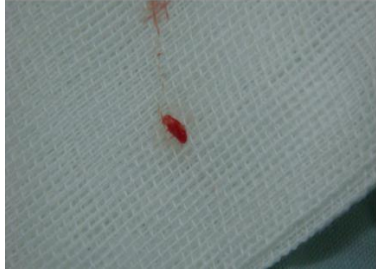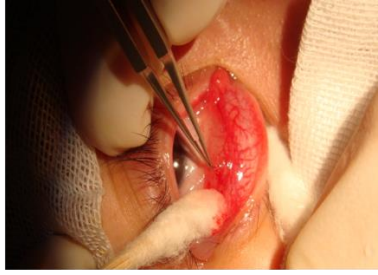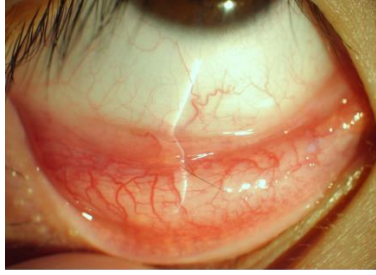
Case 10



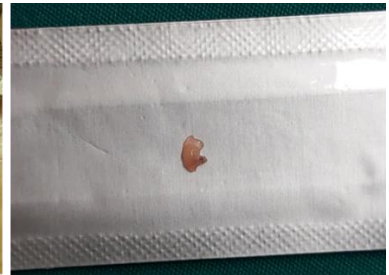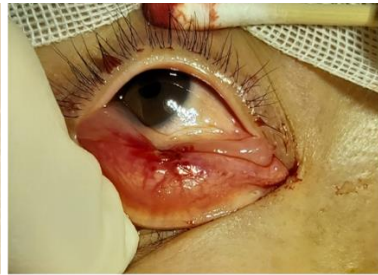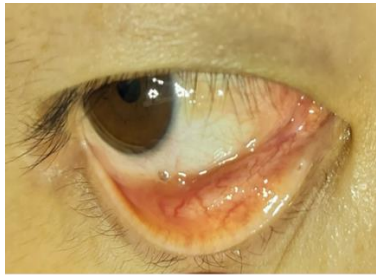
Case 11



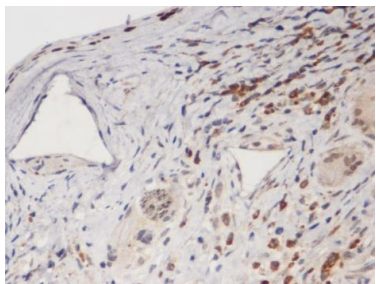
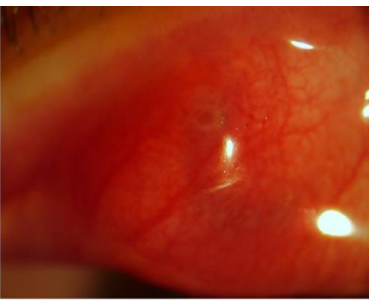
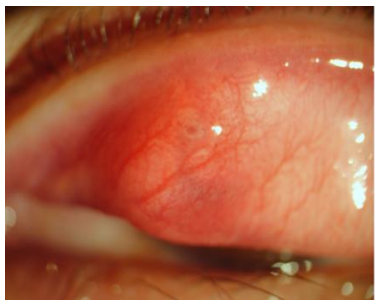
Case 12



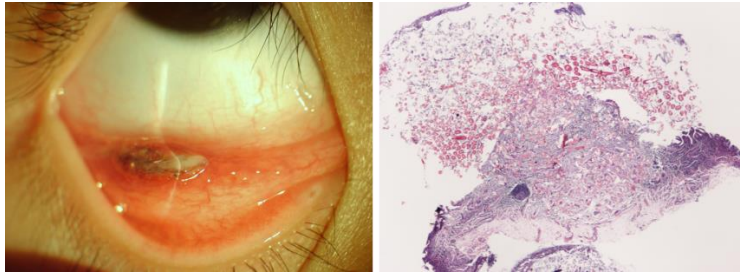
Case 13



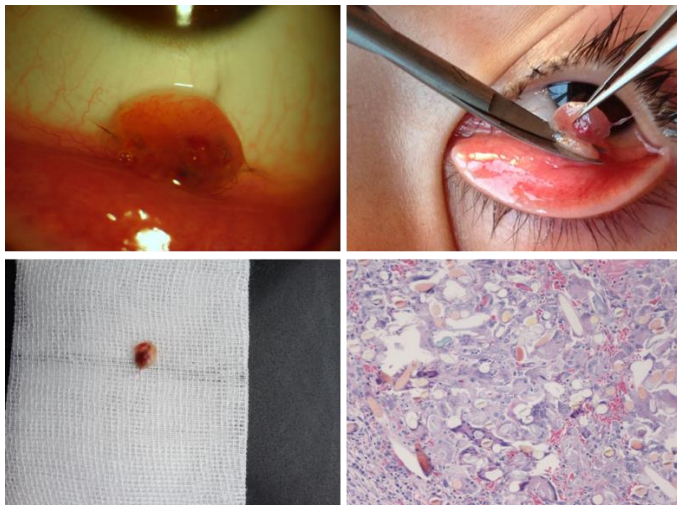
Case 14



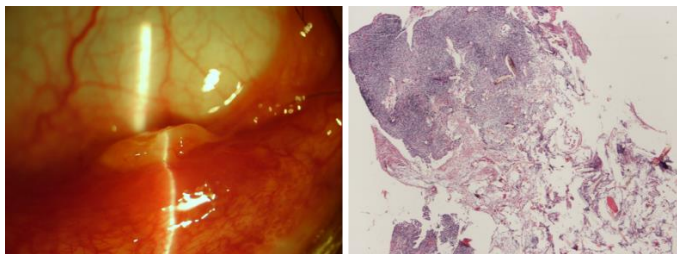
Case 15



Case 16



Case 17



Case 18

