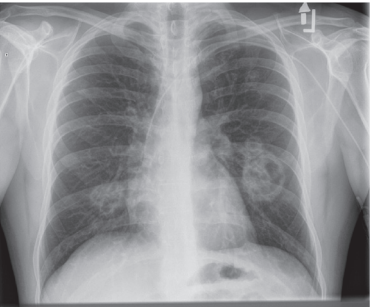


**Pre-treatment X-rays showing
cavitating granulomas**



**Post-treatment X-rays showing
substantial resolution**

