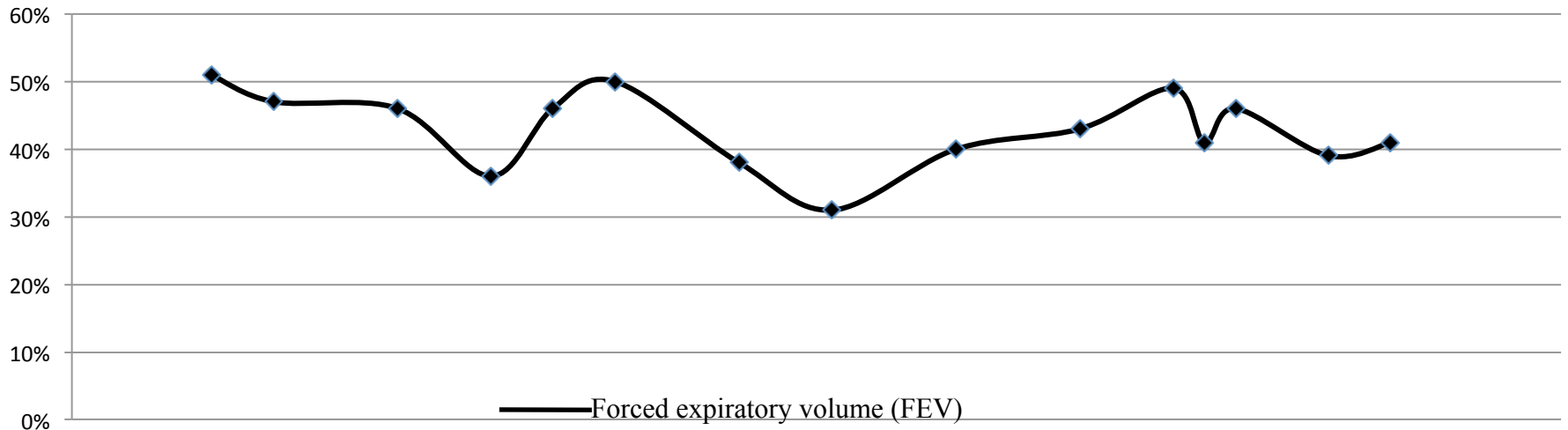
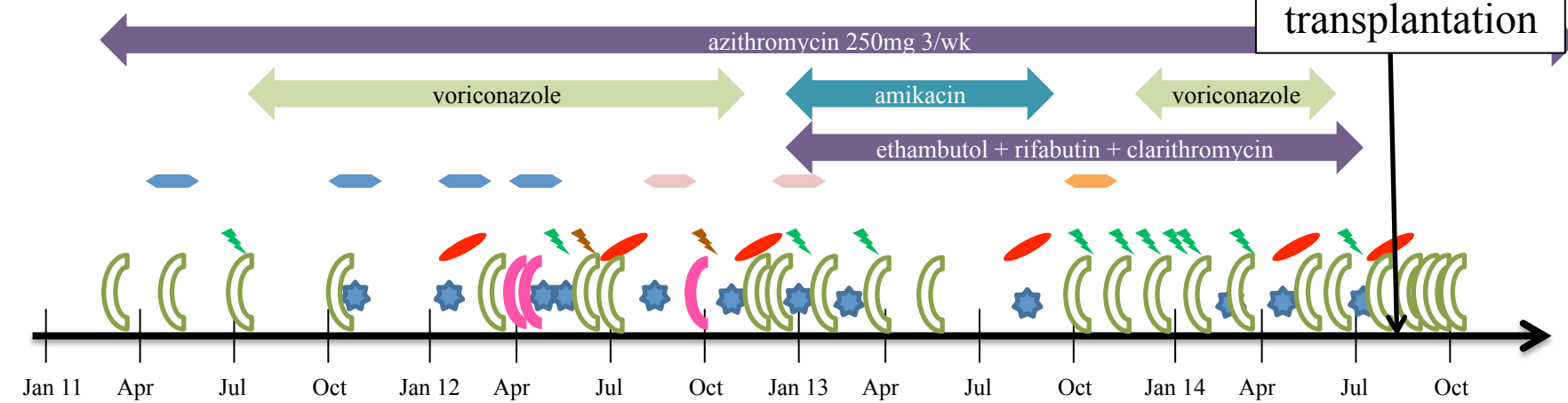


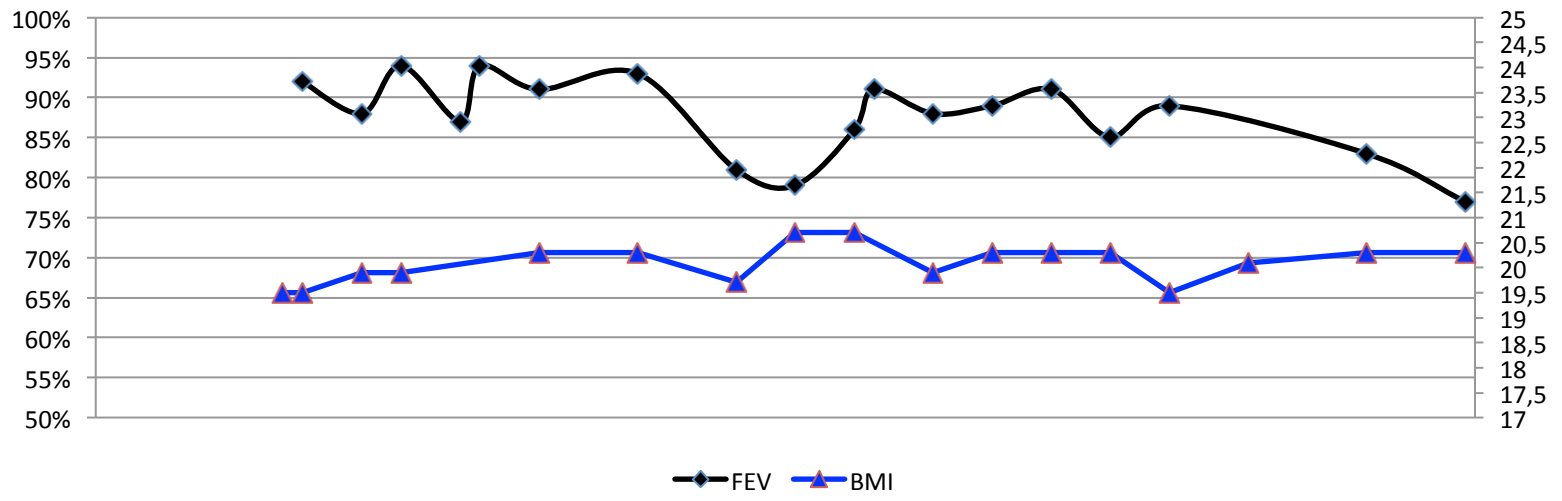
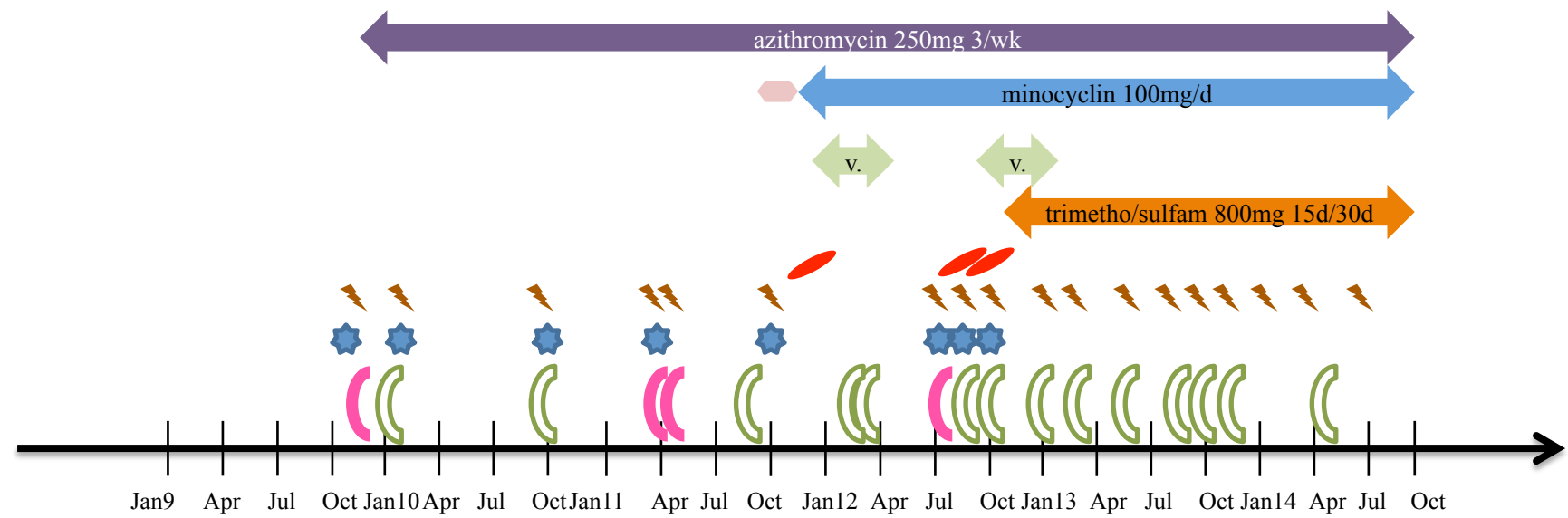
17-year old male patient



Lung transplantation



- Methicillin susceptible *Staphylococcus aureus*
- Mycobacterium lentiflavum* isolation**
- Negative culture for mycobacteria
- ceftazidime + tobramycin 15d
- ceftazidime + trimethoprim/sulfamethoxazole (+ciprofloxacin in Sep 2012) 15d
- meropenem
- Scedosporium apiospermum*
- Aspergillus fumigatus*
- Gram negative bacilli : *Achromobacter* sp., *Pseudomonas* sp., *Serratia* sp., *Stenotrophomonas* sp.

36-year old male patient



 Amoxicillin/clavulanate 15d then oxacillin 15d + ciprofloxacin 1mo
 Voriconazole 200mg/d