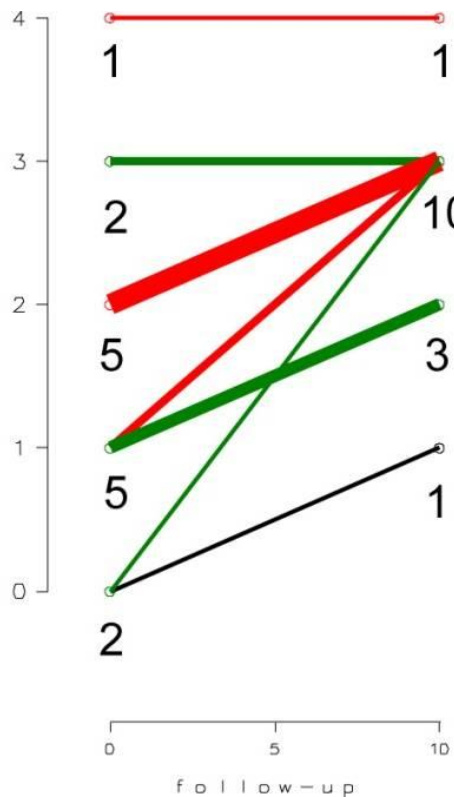


Syndesmophyte score



Radiologic grading of ankylosing spondylitis according to Devogelaer, at baseline and follow-up.

Grade	Radiological severity
0	Isolated sacroiliitis (no syndesmophytes)
I	Incipient syndesmophytes
II	Syndesmophytes bridging 1 or 2 intervertebral disc space
III	Syndesmophytes producing an undulating vertebral contour (bamboo spine)
IV	“trolley track” sign