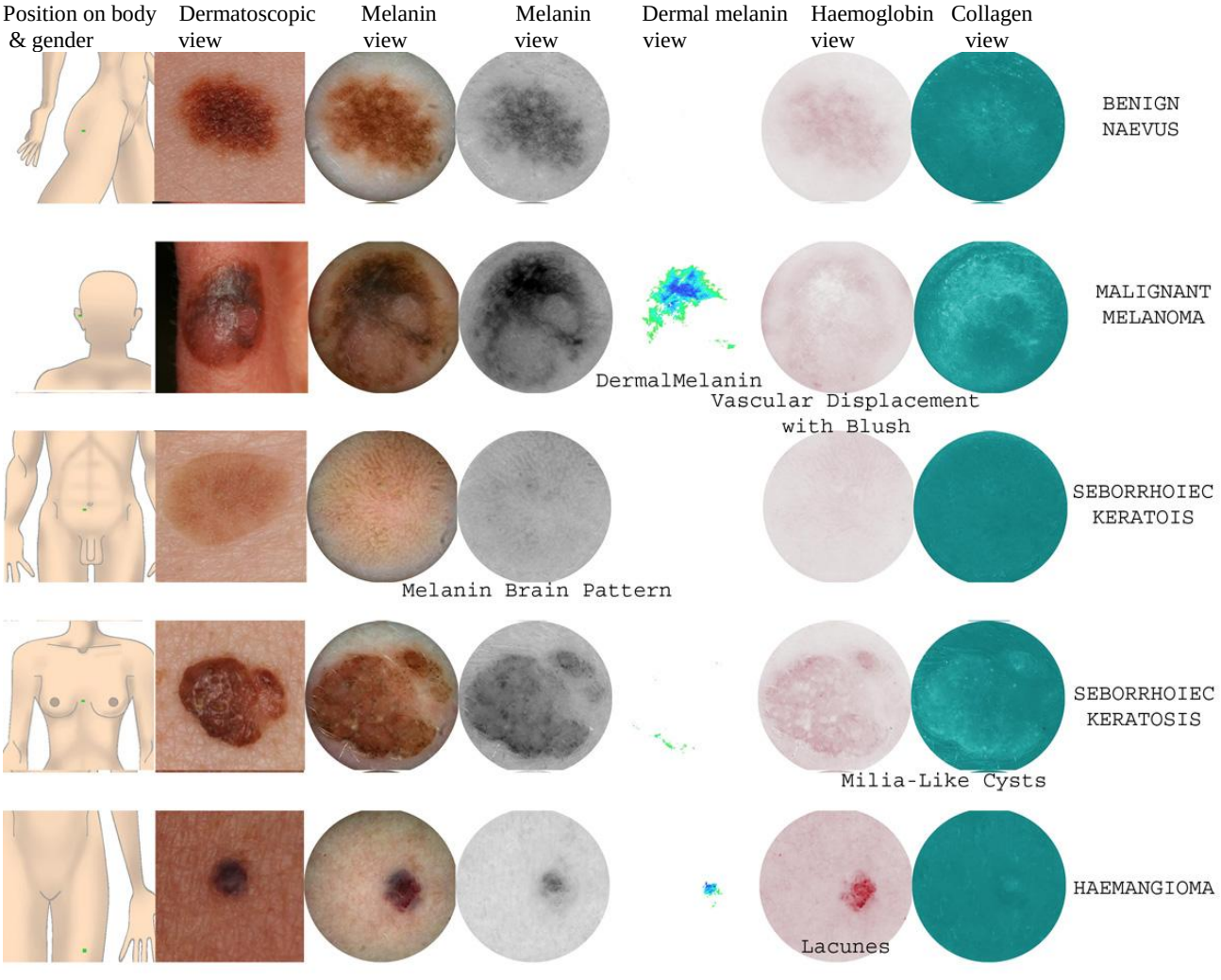
Position on body & gender
Dermatoscopic view
Melanin view
Melanin view
Dermal melanin view
Haemoglobin view
Collagen view
BENIGN NAEVUS
MALIGNANT MELANOMA
DermalMelanin
Vascular Displacement with Blush
SEBORRHOIEC KERATOIS
Melanin Brain Pattern
SEBORRHOIEC KERATOSIS
Milia-Like Cysts
HAEMANGIOMA
Lacunes