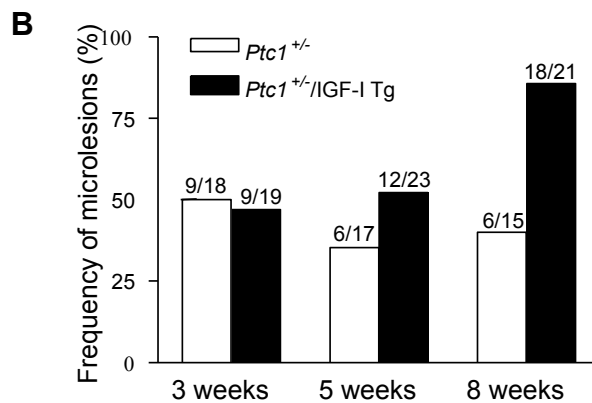
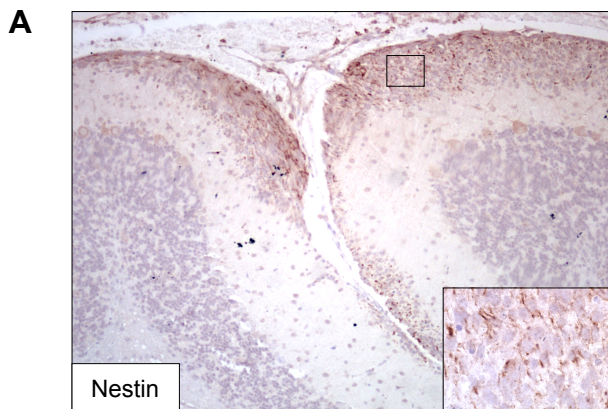


Preneoplastic MB lesions



Fully developed MB

