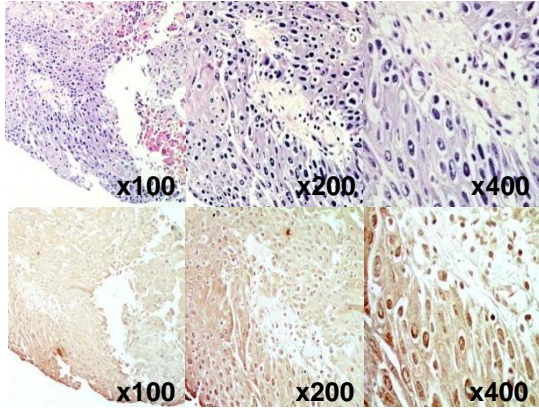
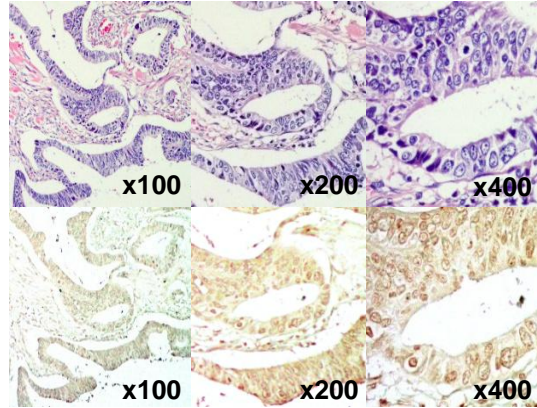


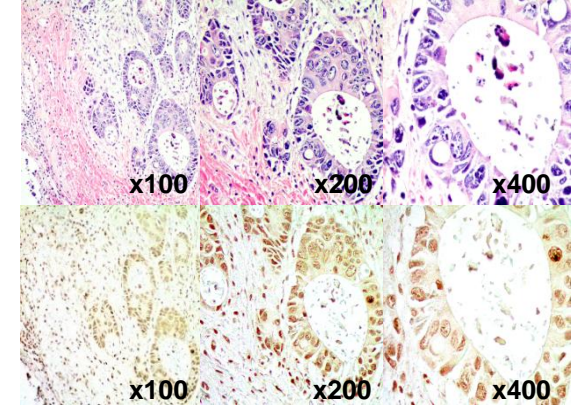
A Bladder, Tumor
Histology: squamous cell carcinoma
Age: 71
Gender: Male
Grade: G1
TNM: T1N0M0



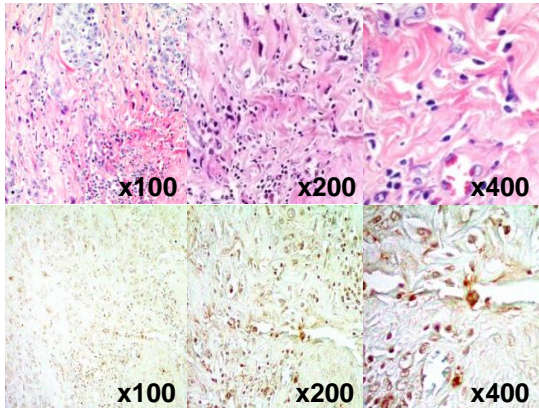
B Bladder, Tumor
Histology: adenocarcinoma
Age: 76
Gender: Male
Grade: G2
TNM: T2N0M0



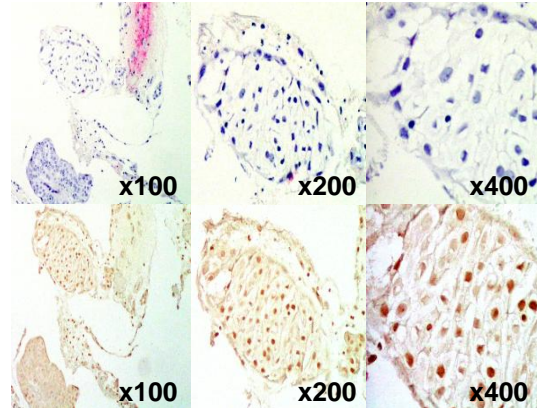
C Bladder, Tumor
Histology: adenocarcinoma
Age: 50
Gender: Male
Grade: G2
TNM: T2N0M0



D Bladder, Tumor
Histology: adenocarcinoma
Age: 68
Gender: Male
Grade: G3
TNM: T2N0M0



E Bladder, Tumor
Histology: transitional cell carcinoma
Age: 49
Gender: Female
Grade: G1
TNM: T1N0M0



F Bladder, Tumor
Histology: transitional cell carcinoma
Age: 64
Gender: Male
Grade: G3
TNM: T3N2M1

