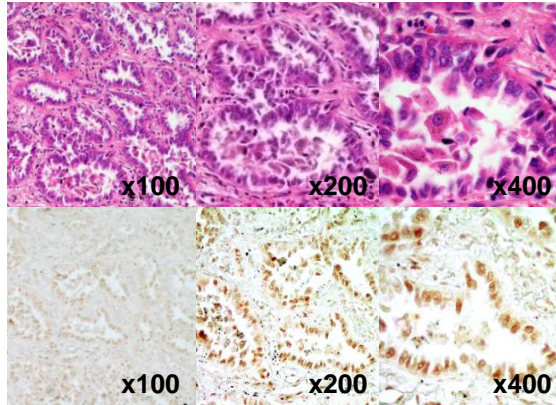
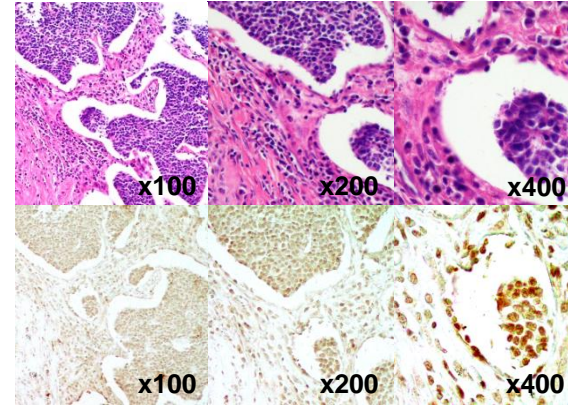


A

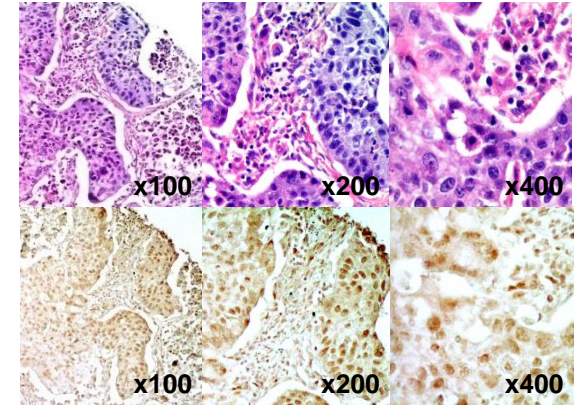
Lung, Tumor
 Histology: adenocarcinoma, papillary
 Age: 59
 Gender: Female
 Tumor history: 1 M+
 Tumor size (cm): 4x3.5x2.5
 Differentiation: well
 TNM: T2N0M0

**B**

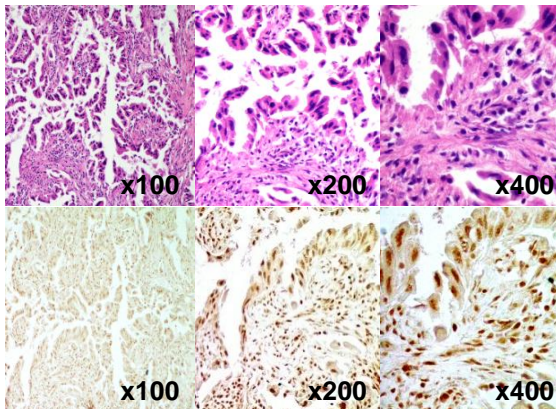
Lung, Tumor
 Histology: squamous cell carcinoma
 Age: 70
 Gender: Male
 Tumor history: 1 M+
 Tumor size (cm): diameter 3.2
 Differentiation: poorly
 TNM: T2N0M0

**C**

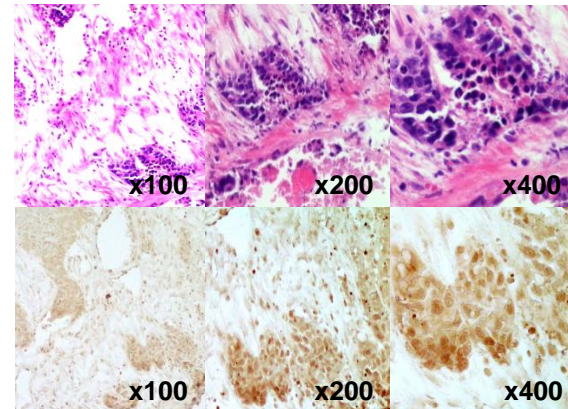
Lung, Tumor
 Histology: squamous cell carcinoma
 Age: 65
 Gender: Male
 Tumor history: 2 M+
 Tumor size (cm): 15x10x12
 Differentiation: moderately
 TNM: T2N0M0

**D**

Lung, Tumor
 Histology: alveolus cell carcinoma
 Age: 60
 Gender: Female
 Tumor history: 1 M
 Tumor size (cm): 3x2.5x2
 Differentiation: N/A
 TNM: T2N0M0

**E**

Lung, Tumor
 Histology: squamous cell carcinoma
 Age: 69
 Gender: Male
 Tumor history: 40 D
 Tumor size (cm): 5x4x4
 Differentiation: poorly
 TNM: T2N1M0

**F**

Lung, Tumor
 Histology: alveolus cell carcinoma
 Age: 78
 Gender: Male
 Tumor history: 6 M+
 Tumor size (cm): 1.5x0.5x0.3
 Differentiation: moderately
 TNM: T1N0M0

