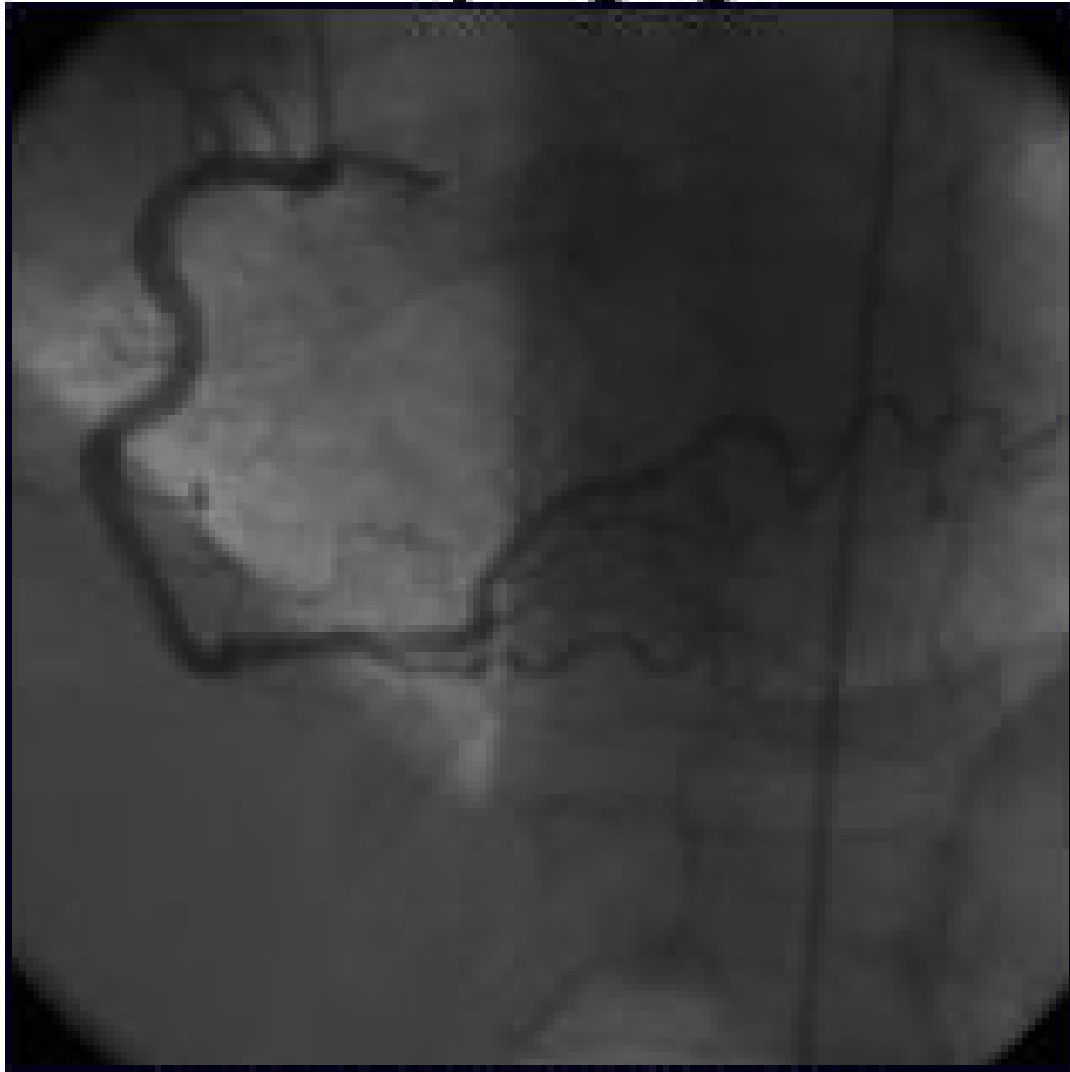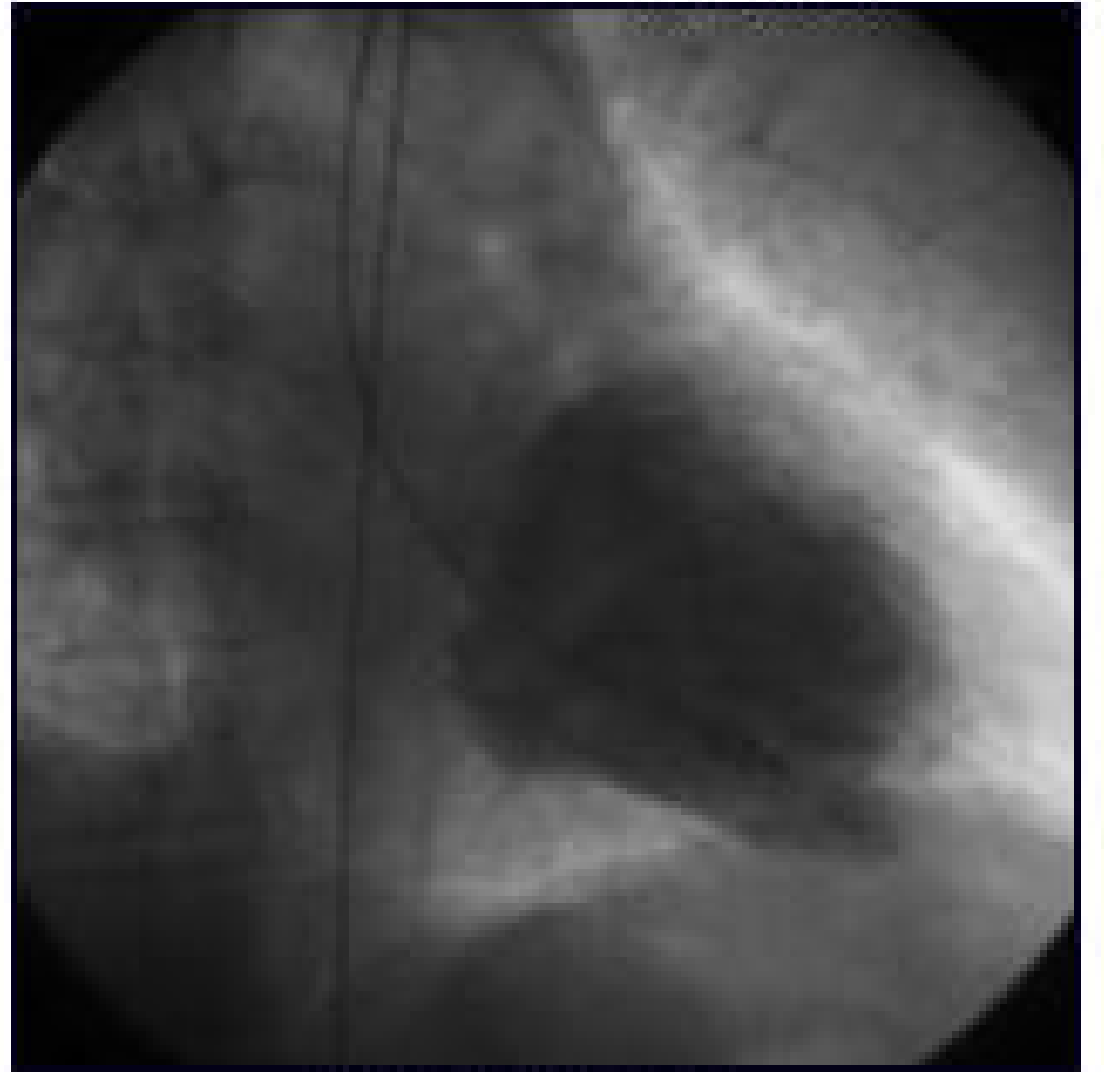


Coronary angiogram

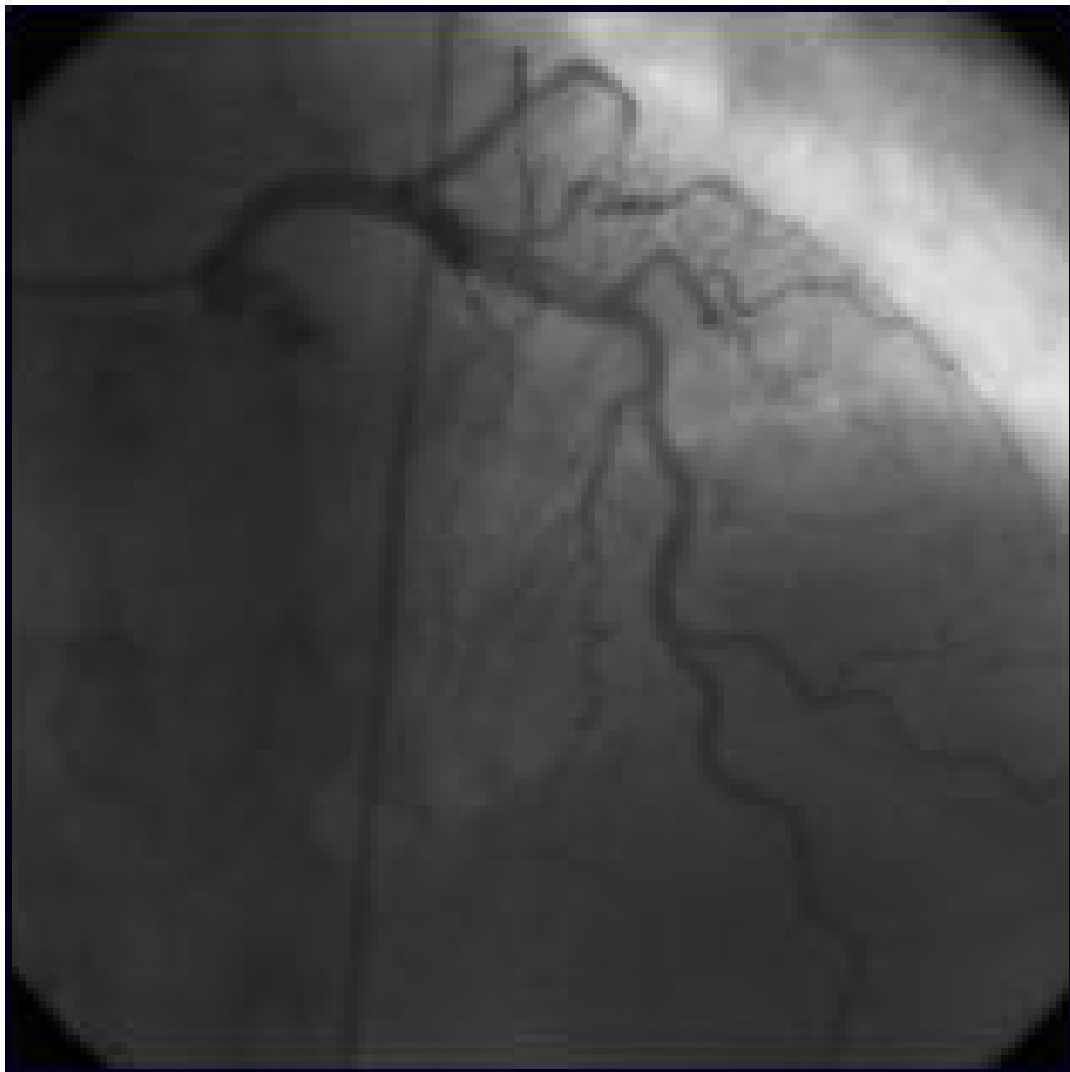


Right coronary artery

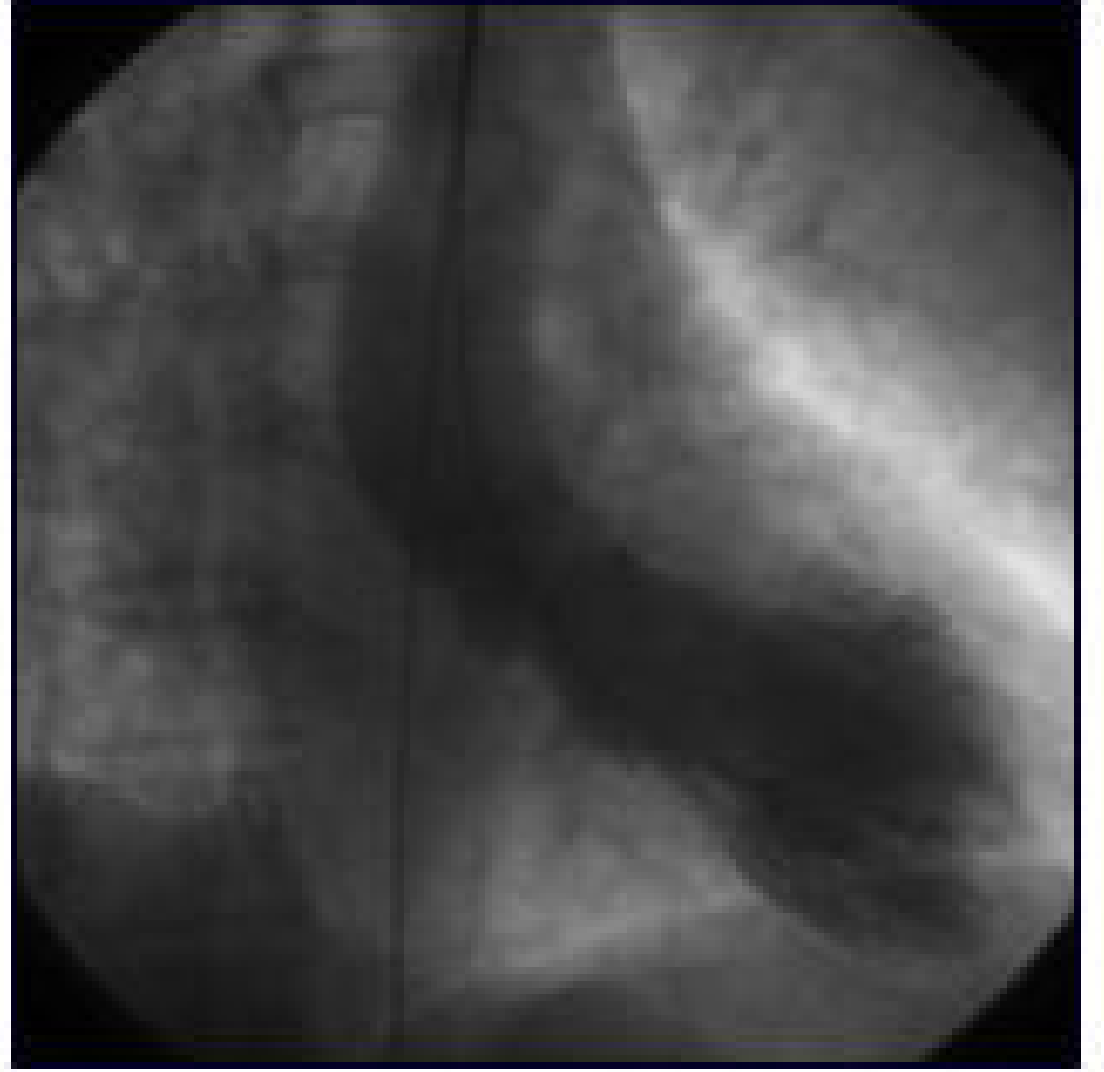
Left ventriculography



End-diastole



Left coronary artery



End-systole