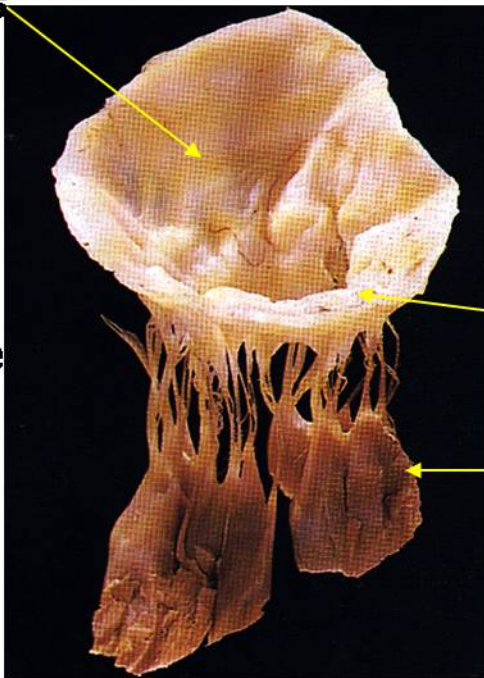


**Leaflets**



**Chordae**

**Annulus**

**Papillary  
muscles**

**Ventricular wall**