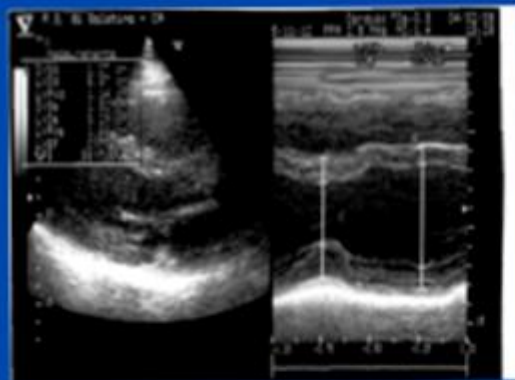
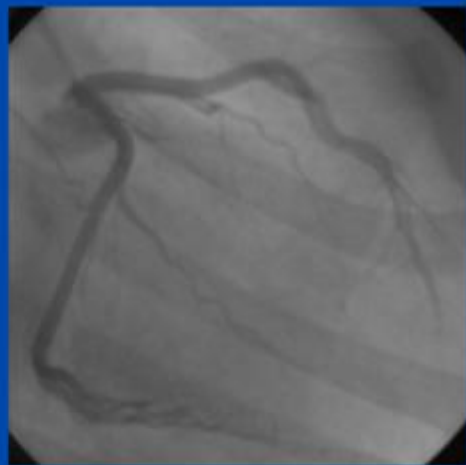
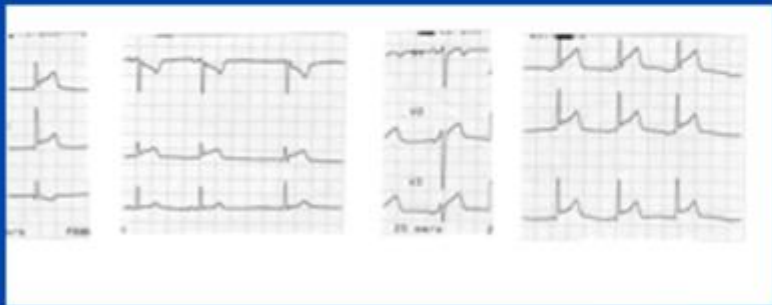

P. C., male, 18 y

Chest pain +++



Tp I = 2,6 ng/ml

22.1.2008