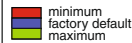

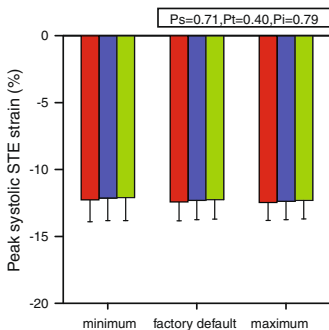
Regional circumferential strain

Temporal smoothing



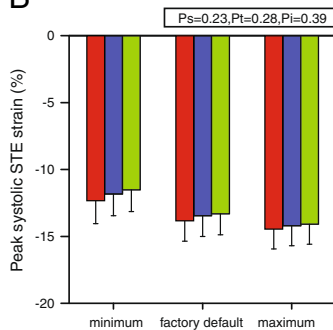
A

Anterior wall

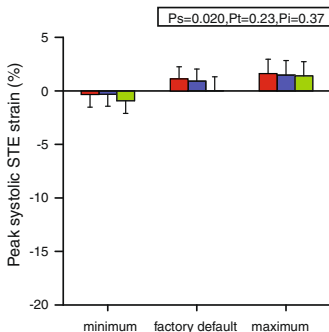


B

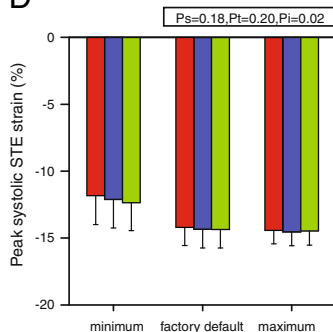
Posterior wall



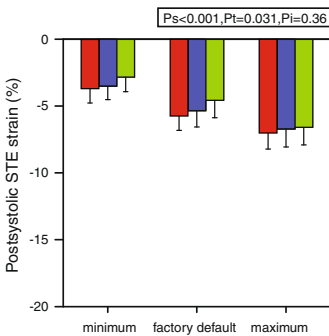
C



D



E



F

