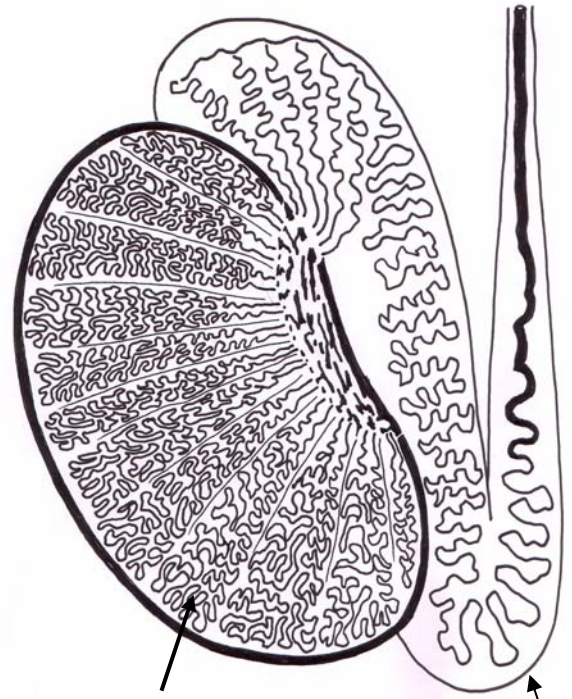


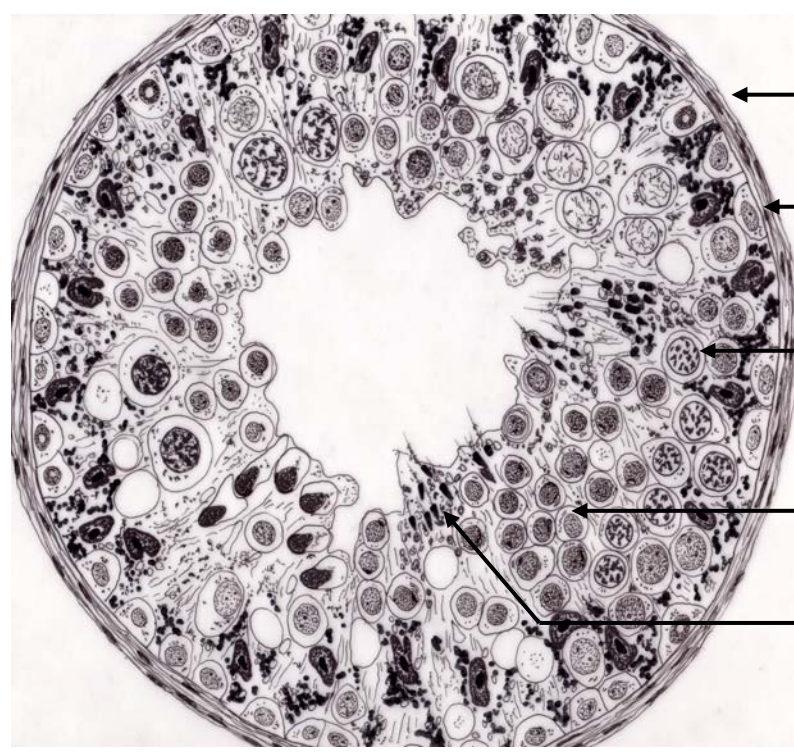
Tunica albuginea
 Lobulus testis
 Rete testis

A



Lobulus testis = loop of seminiferous tubule
 Epididymis

B



Peritubular tissue
 (Lamina propria of seminiferous tubule)
 Spermatogonium
 Primary spermatocyte
 Immature spermatids
 Mature spermatids

C