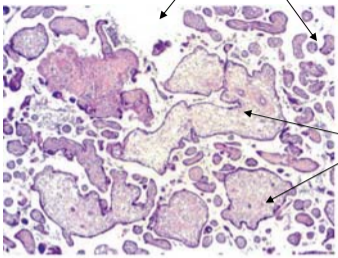


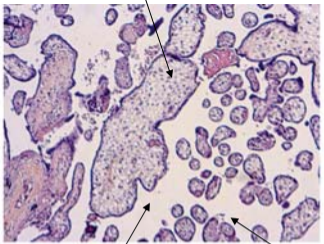
Diffuse mature villi hypoplasia



Hydropic immature villi

Trisomy 21

Immature villi

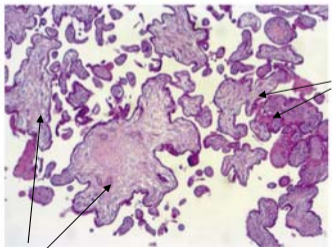


Enlarged inter villi chamber

Major mature villi hypoplasia

Trisomy 18

Numerous regular mature villi



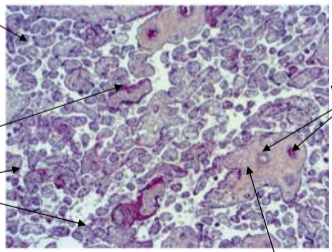
Immature hydropic villi

Trisomy 13

Fibrin deposits

Fibrin deposits

Trophoblastic tissue



Fetal vessels

Control

Vascularised villous tree