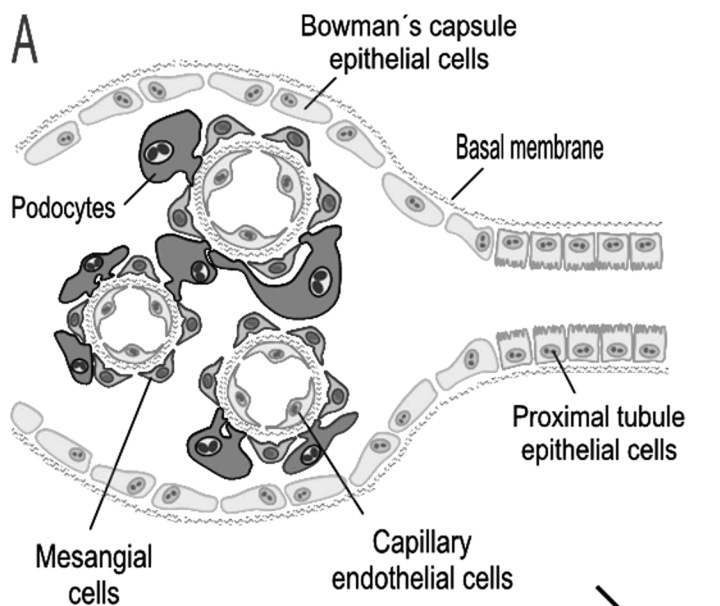
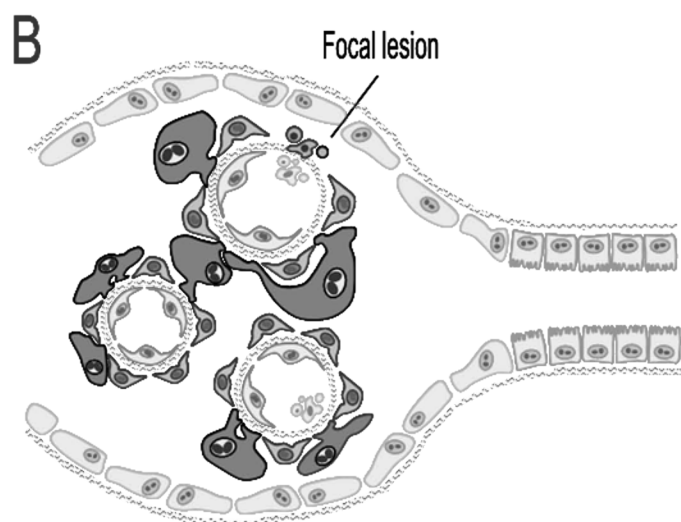


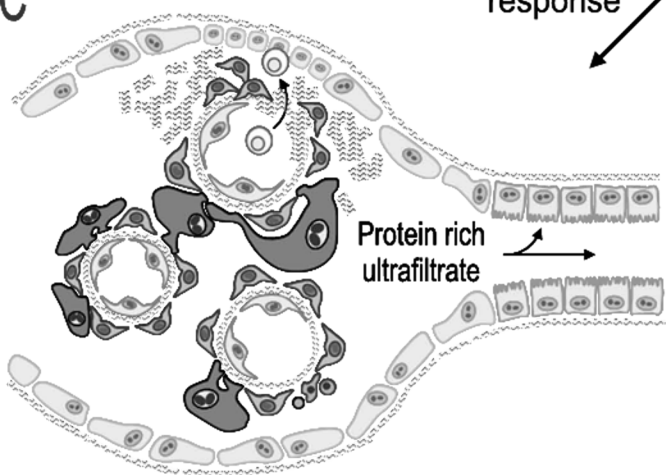
# Glomerular degeneration and glomerulosclerosis in CKD



Initial damage



Pathological response



Degeneration and sclerosis

