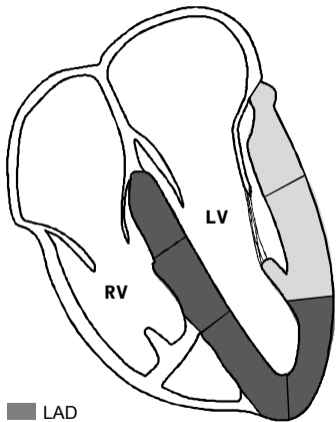
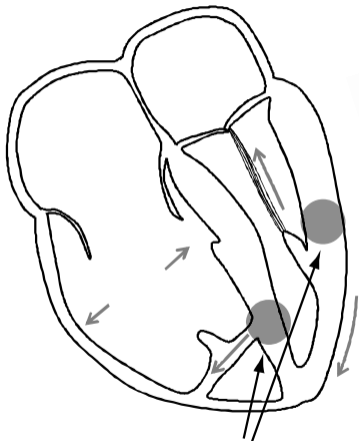


**LV-RV GEOMETRY UNDER
NORMAL CONDITION**

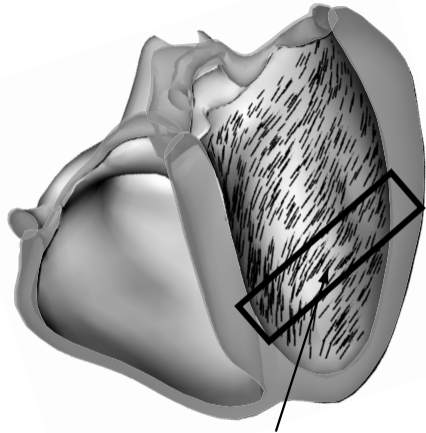


**LV-RV GEOMETRY
DURING CHEST TRAUMA**



points of increased wall stress

LV ENDOCARDIAL FIBRE ORIENTATION



fibres of increased wall stress

■ LAD
■ LCx