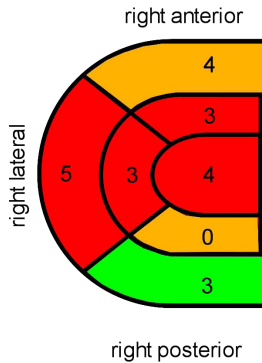
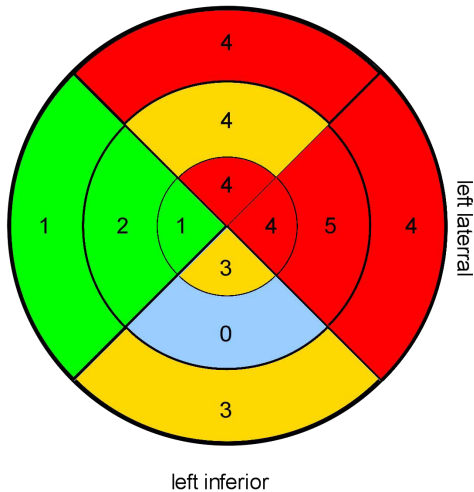


left anterior



septum



(A)

(B)