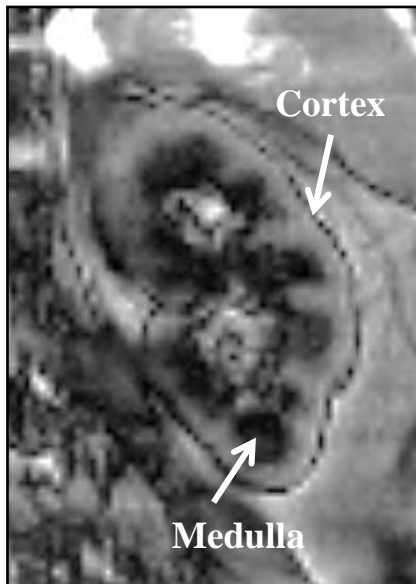
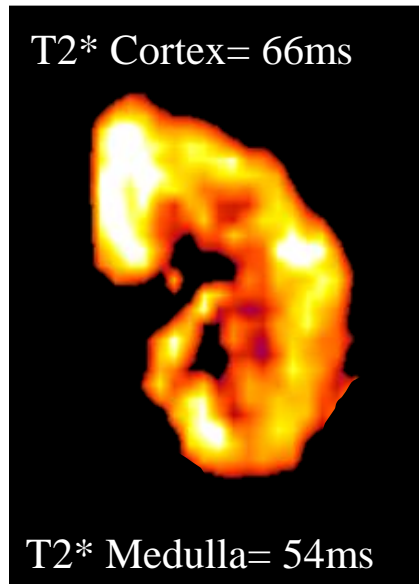


Anatomical Image

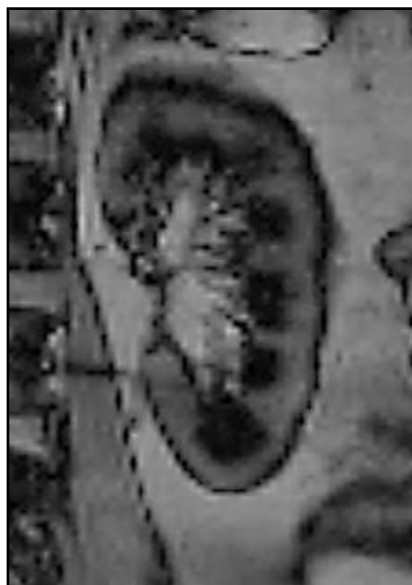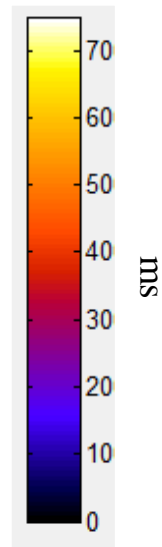
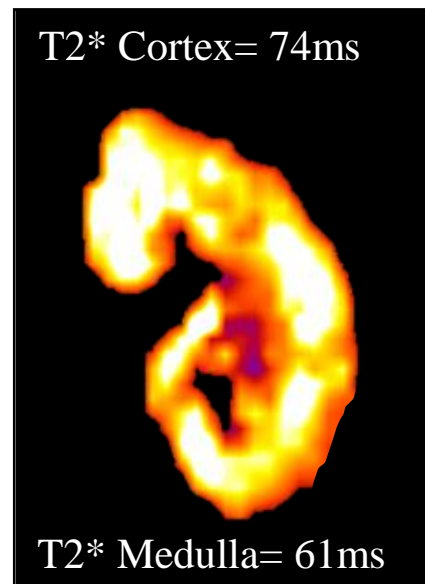


Furosemide-naive patient

Pre-Furosemide BOLD



Post-Furosemide BOLD



Patient chronically receiving furosemide 40mg daily

