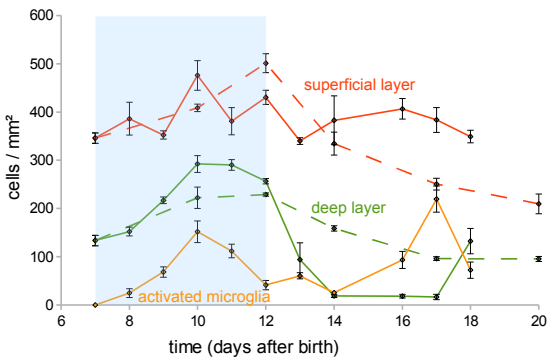
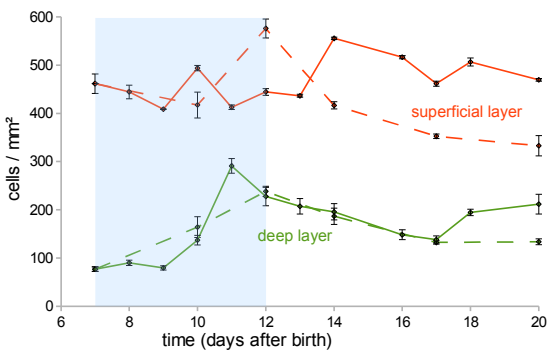


Microglial cells in the central avascular zone



Microglial cells in the peripheral zone



Hyalocytes in the vitreous

