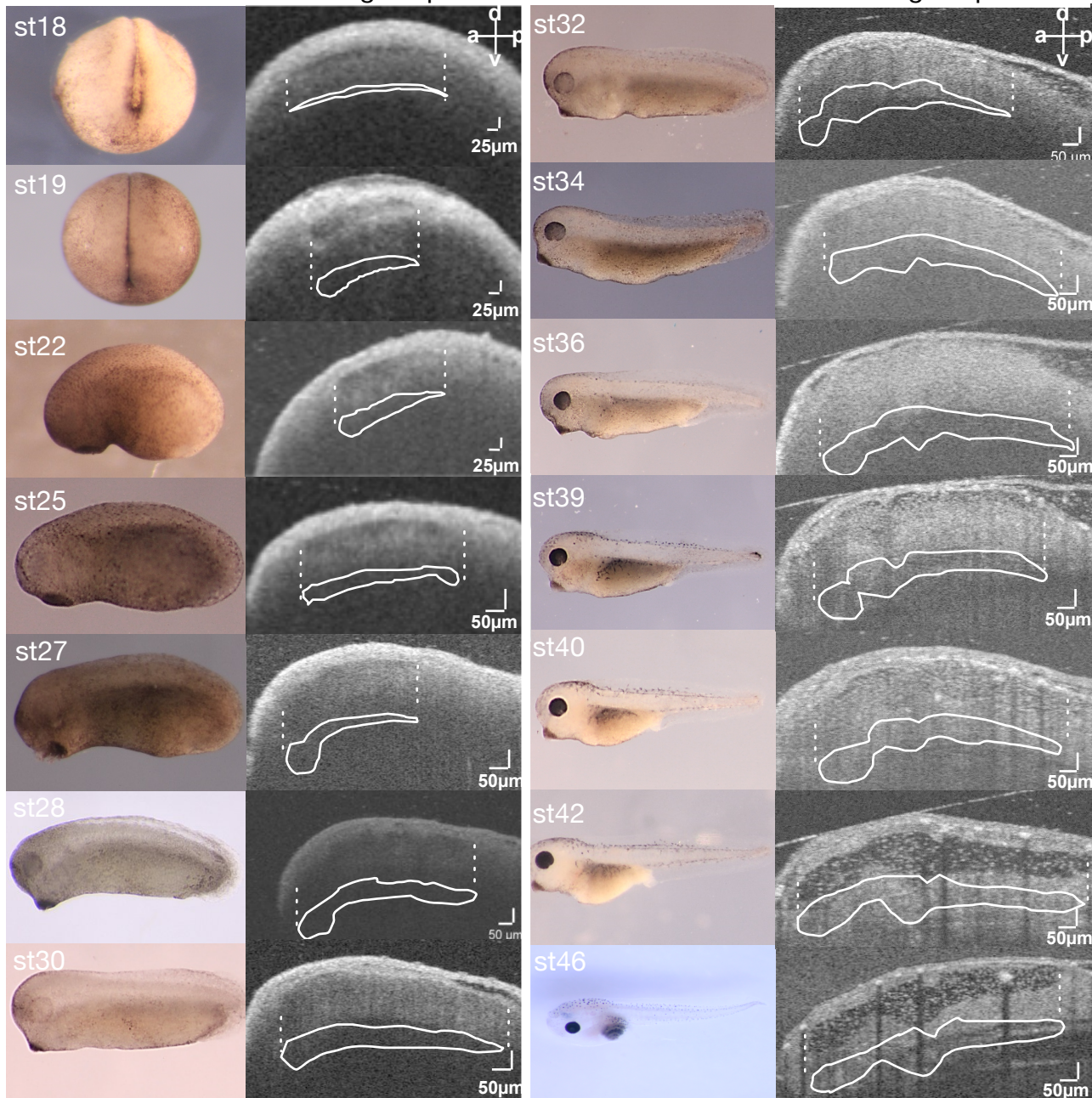


Xenopus tropicalis ventricular development map by OCT imaging

A

Mid-sagittal plane

Mid-sagittal plane



B DORSAL → VENTRAL

Mid-Sagittal Plane

