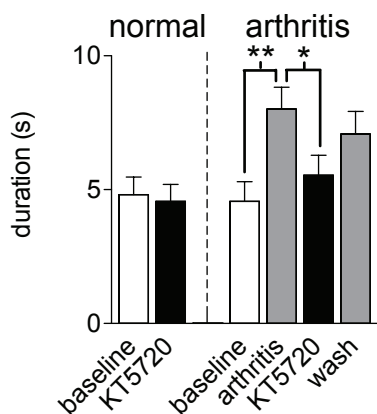
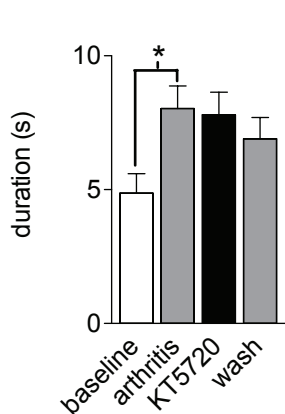


Audible vocalizations

A CeLC

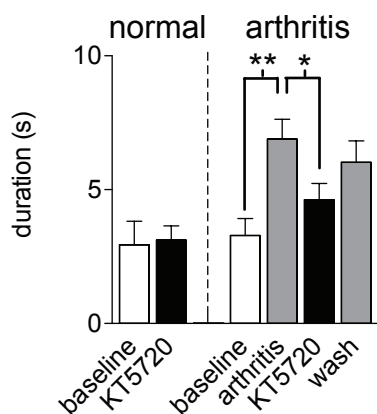


D striatum

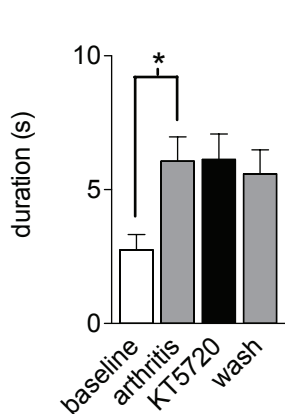


Ultrasonic vocalizations

B CeLC

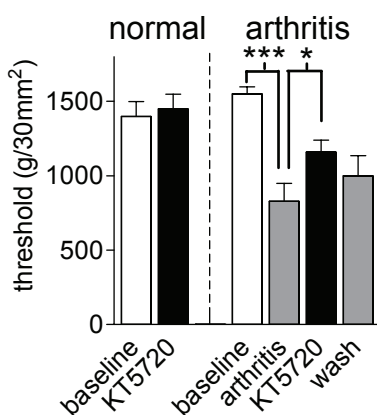


E striatum



Spinal reflex

C CeLC



F striatum

