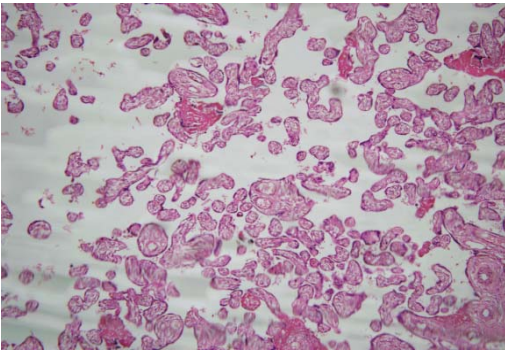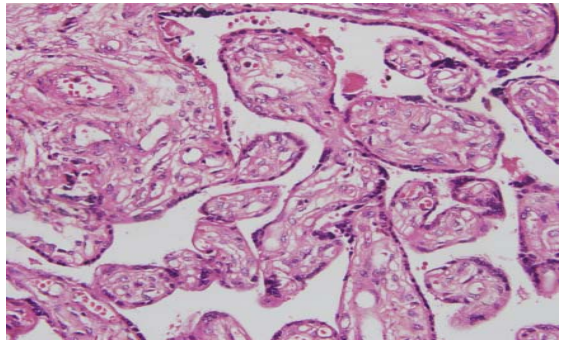
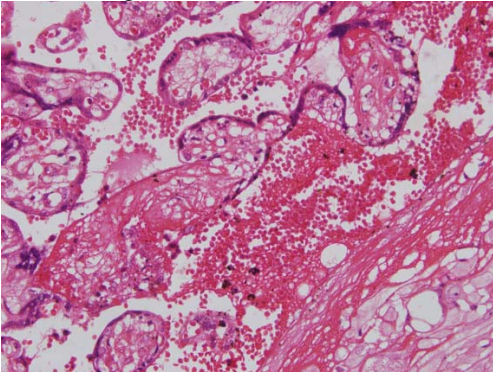


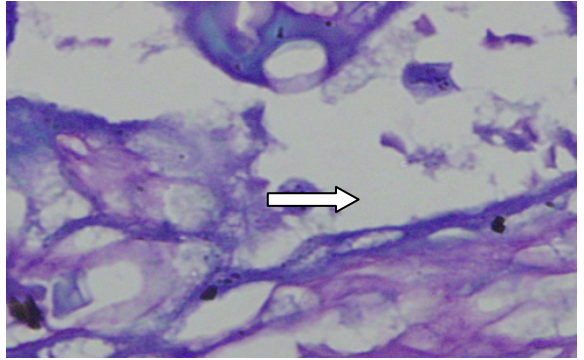
Placenta negative for malaria (H &E × 10)



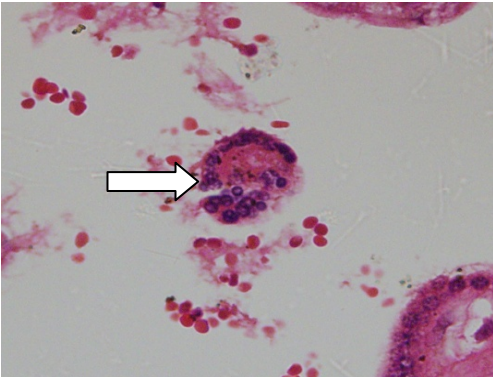
Placenta negative for malaria (H &E × 40)



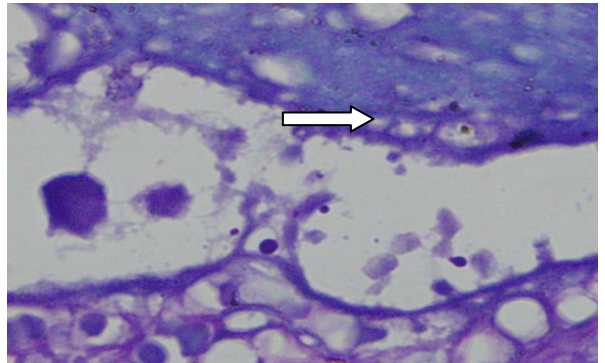
Chronic malaria infection (H&E ×10)



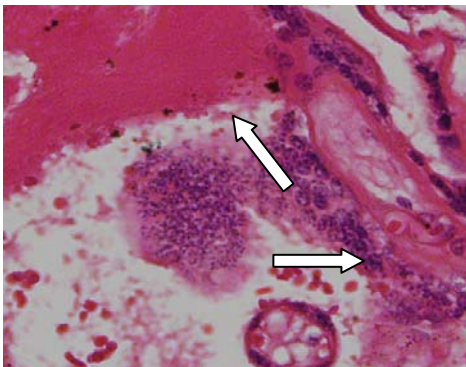
Schizont in chronic malaria infection (Giemsa stain ×100)



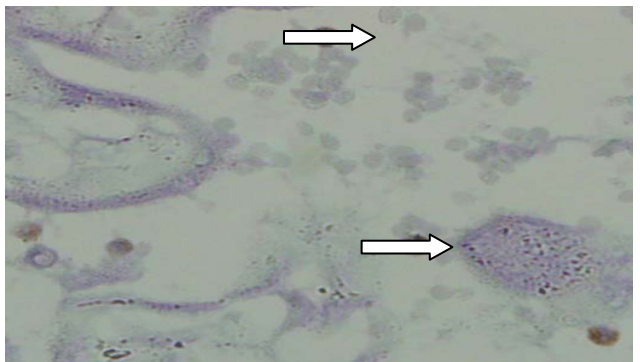
Giant cell in chronic malaria infection



Trophozoite in chronic malaria infection



Fibrin pigment and giant cell in chronic malaria infection (Giemsa × 40)



CD68 Macrophage in placenta with past malaria infection (Immunocytochemistry × 40)