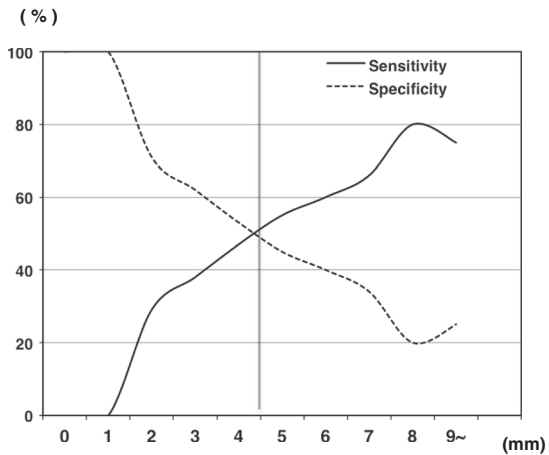


Detection rate of septa in the maxillary sinus on panoramic radiographs



Height of septa in the maxillary sinus