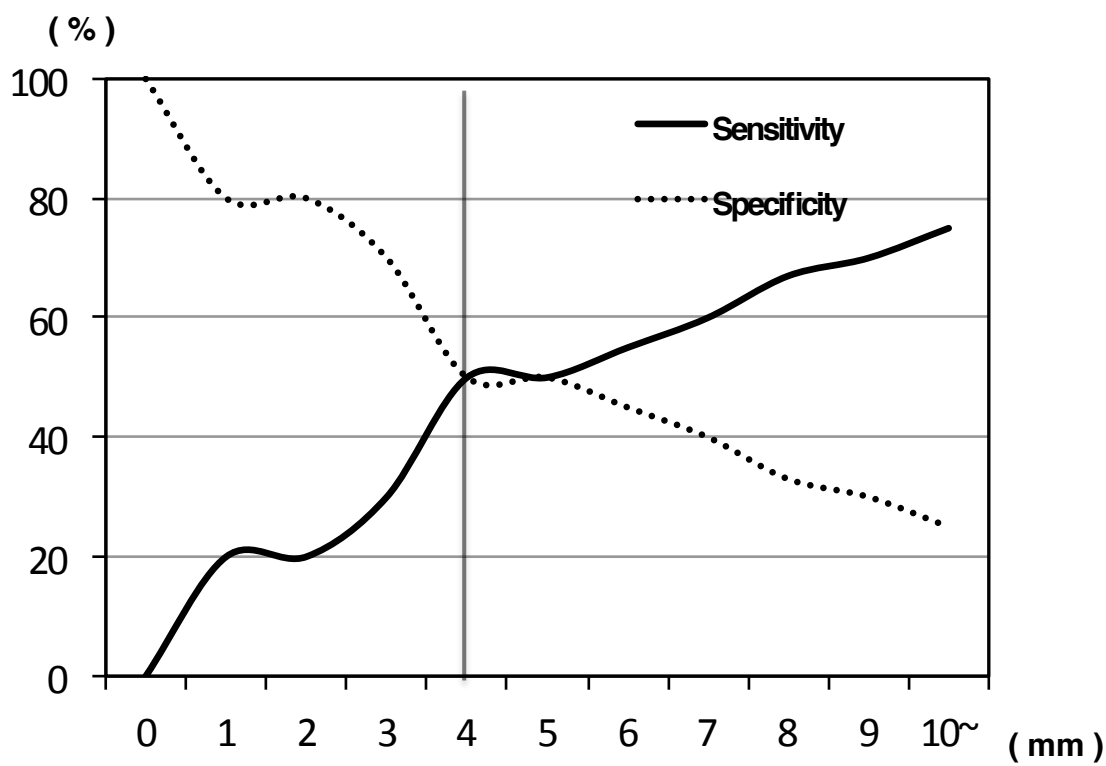


**Dedection rate of SOLs
in the maxillary sinus on
panoramic radiographs**



Major axis length of SOLs in the maxillary sinus

SOLs: Space occupying lesions