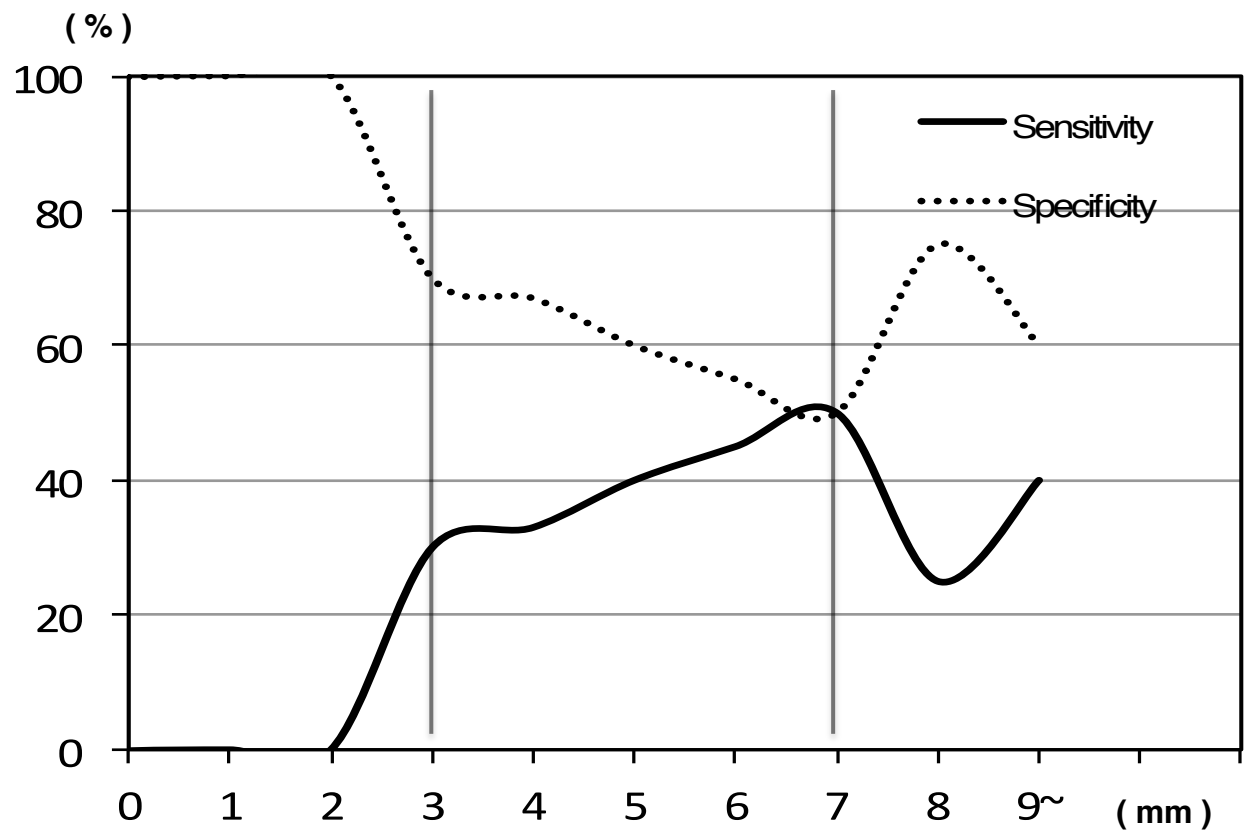


Dedection rate of mucosal thickening in the maxillary sinus on panoramic radiographs



Width of mucosal thickening in the maxillary sinus