

E1

E2

**Clinical Criteria**

- Pelvis translated to the concave lumbar side
- Trunk imbalanced to the convex lumbar side
- Noticeable lumbar prominence with no thoracic hump

**Clinical Criteria**

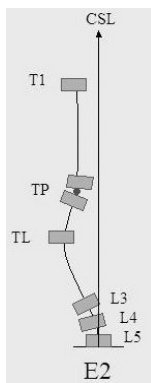
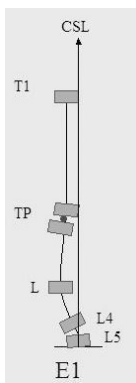
- Pelvis translated to the concave thoracolumbar side
- Trunk imbalanced to the convex thoracolumbar side
- Noticeable thoracolumbar prominence with no thoracic hump

**Radiological Criteria**

- Single lumbar with no thoracic curve
- TP imbalanced to the convex lumbar side according the CSL
- T1 imbalanced to the convex lumbar side

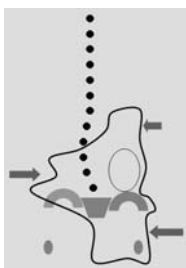**Radiological Criteria**

- Single thoracolumbar with no thoracic curve
- TP imbalanced to the convex thoracolumbar lumbar side according the CSL
- T1 imbalanced to the convex thoracolumbar lumbar side



**Brace Design**

- short lumbar brace



**Brace Design**

- short Thoracolumbar brace

