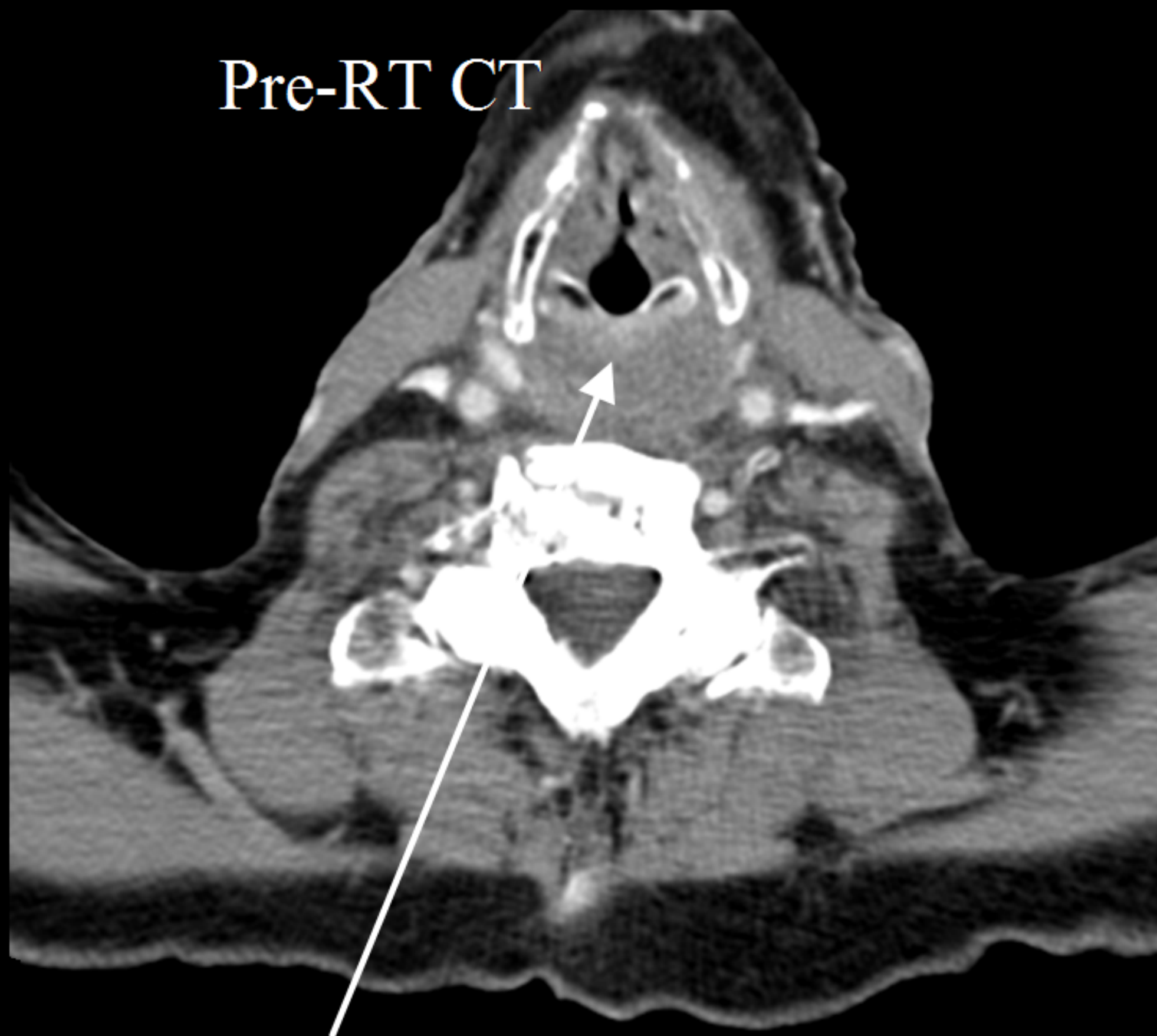
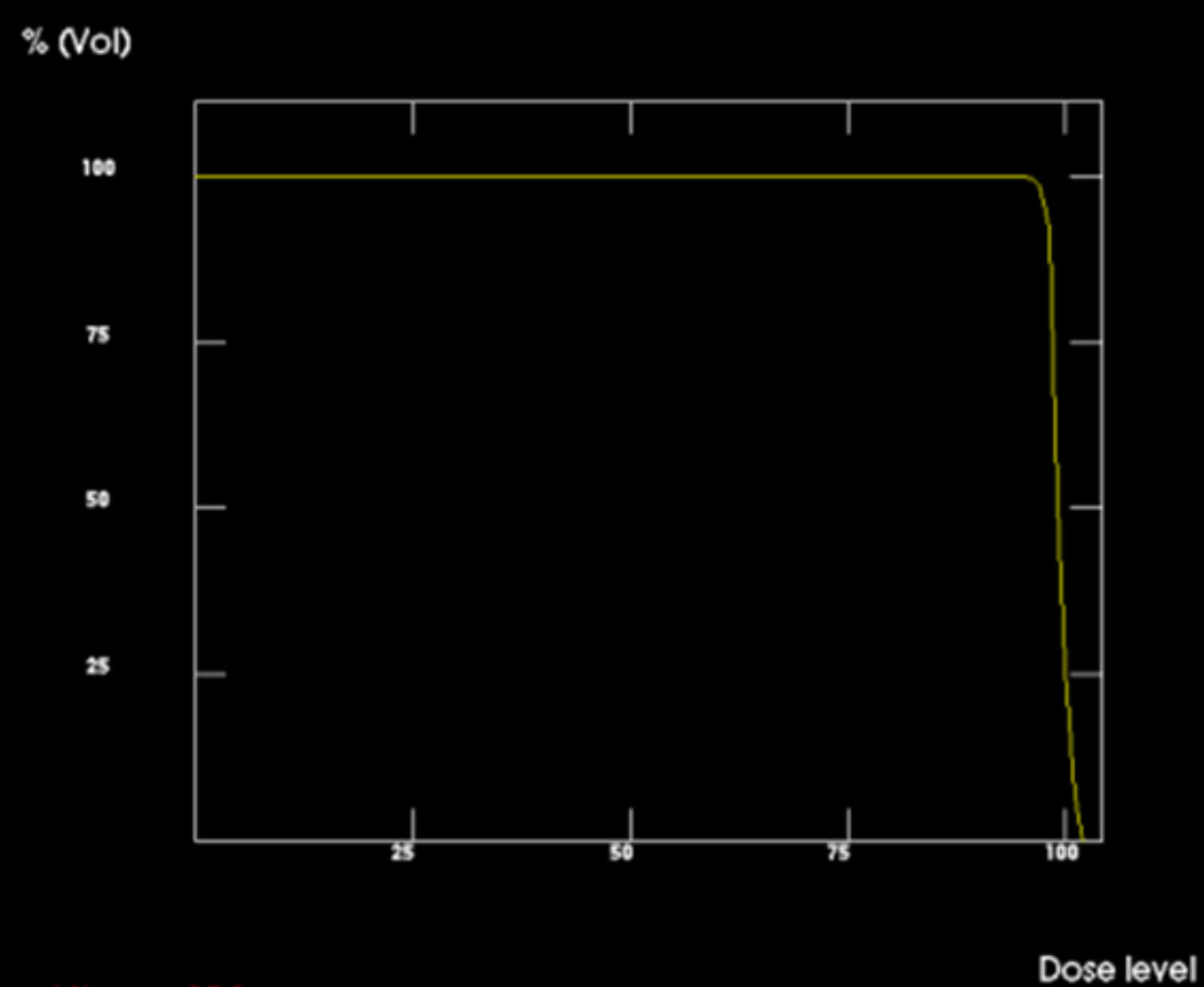


Pre-RT CT



DVH-VOI Id 7 recur  
Volume (ccm): 25.  
Calc. pnts 199 / 199

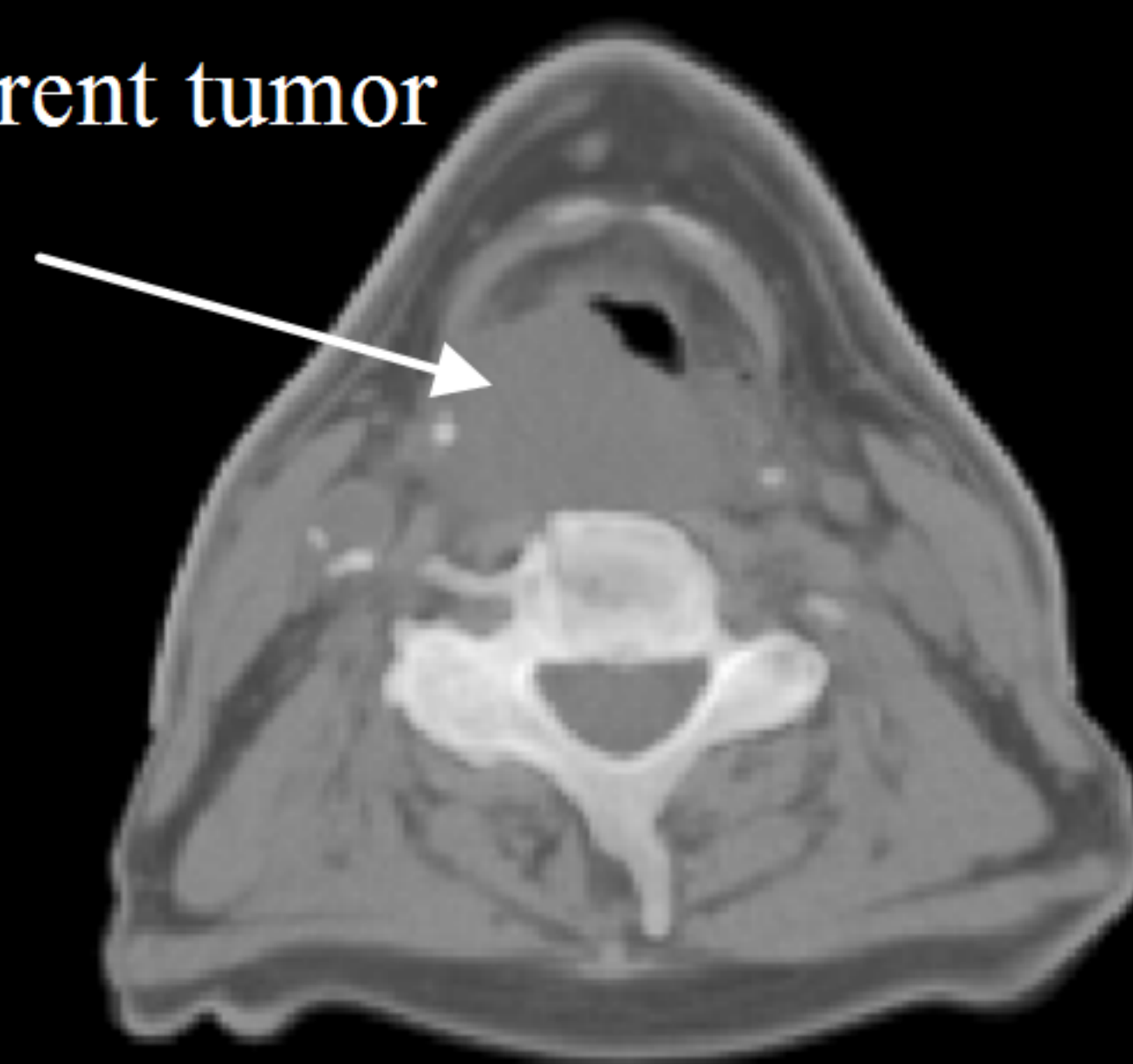
DVH recurrent tumor



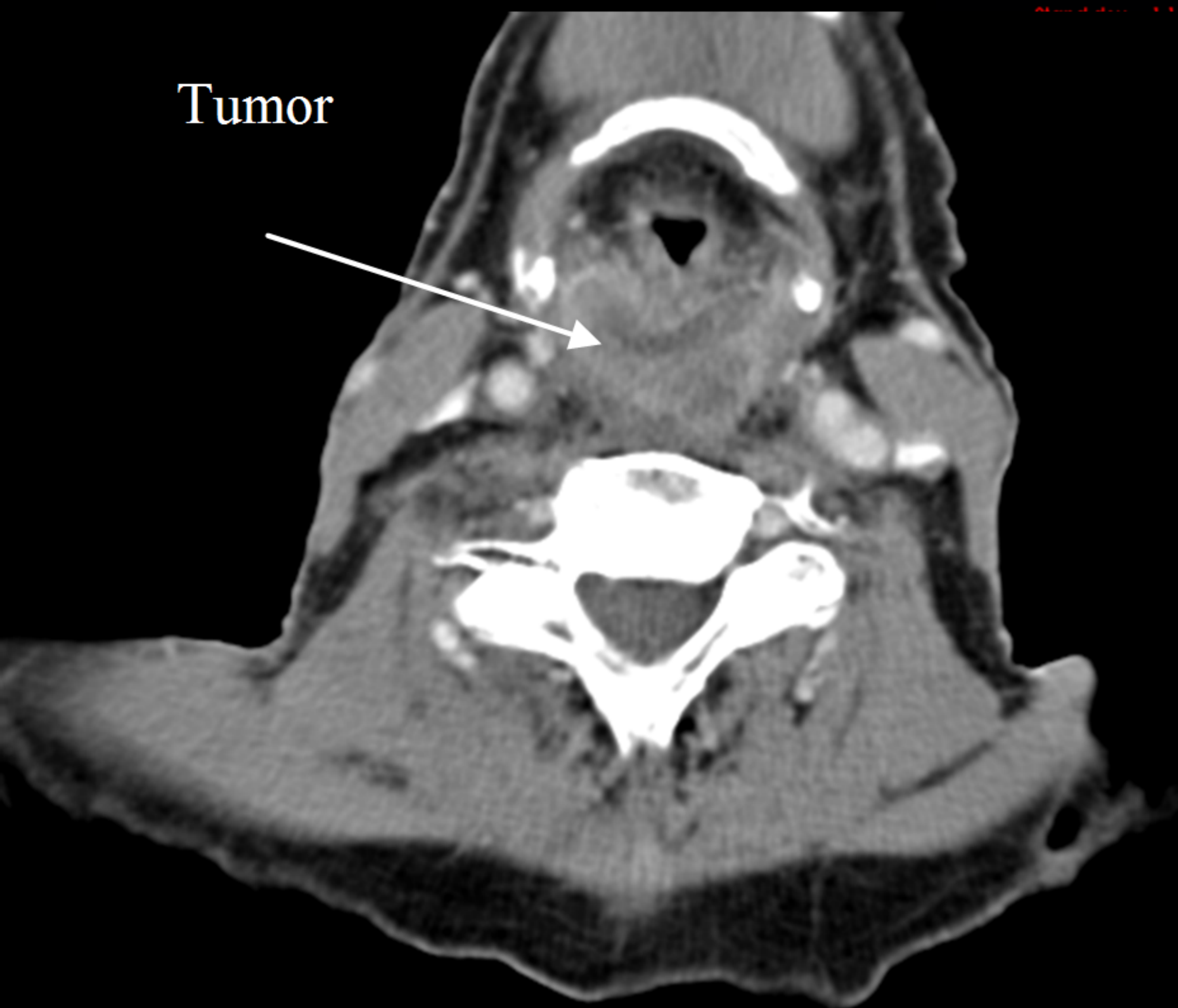
Min 95.9  
Max 101.9  
Median 99.1  
Mean 99.2

Post-RT CT

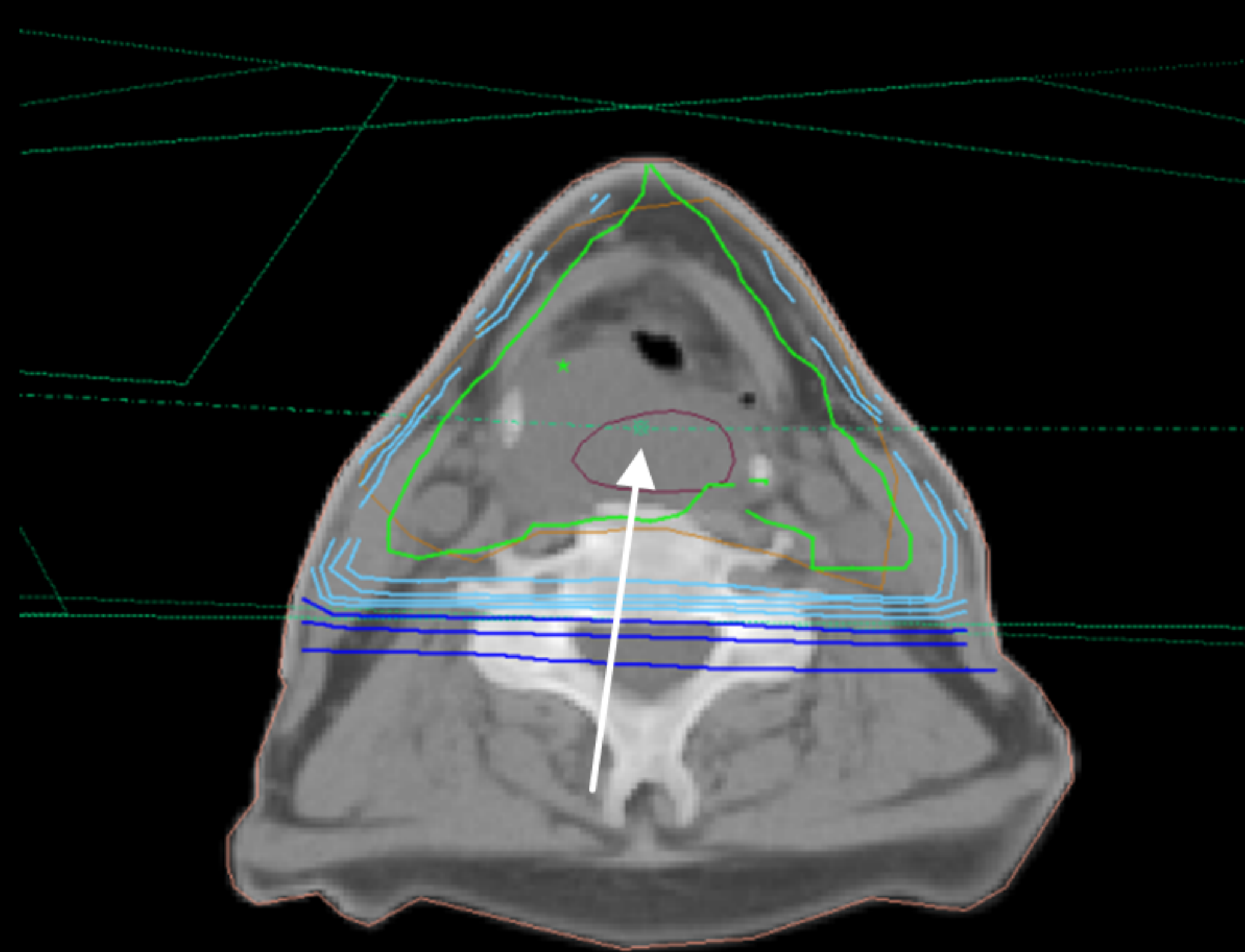
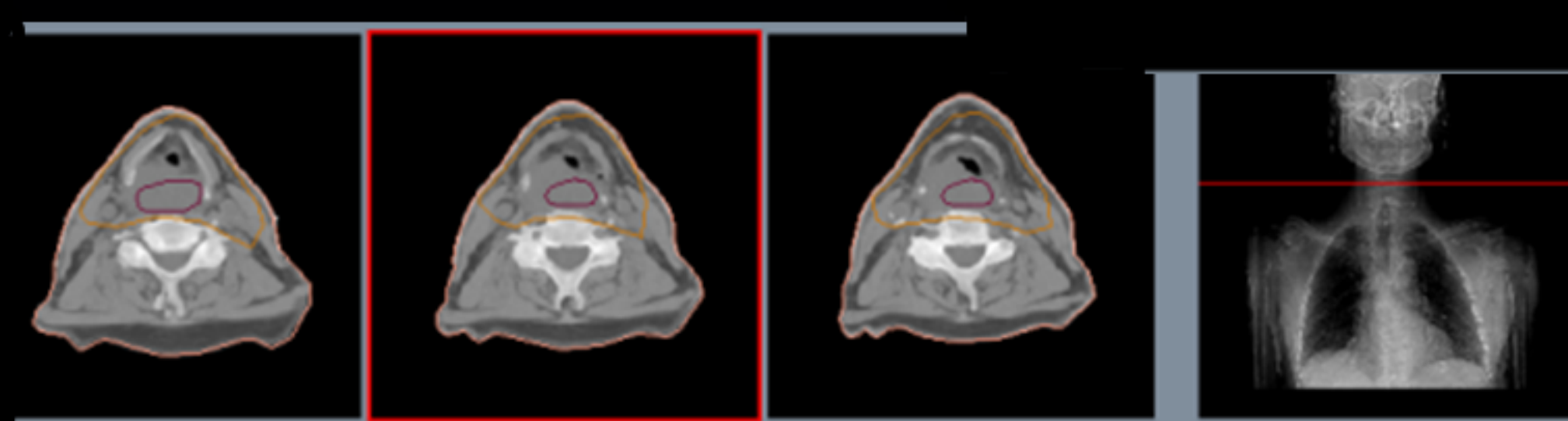
Recurrent tumor



Tumor



pre-RT CT



Recurrent tumor

