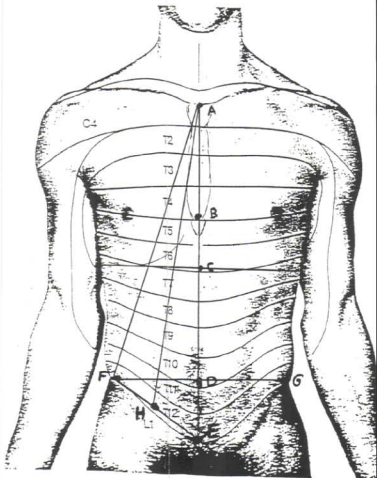


A	Jugular notch
B	End of body of sternum
C	Middle of transpyloric line
D	Middle of trans-SA iliac crest
E	Pubic symphysis
F	R 'Superior anterior iliac crest
G	L 'Superior anterior iliac crest
H	Middle of trans-'R' SAIC-Pubic symphysis



K	End of Left Subclavian
L	Celiac artery
M	Renal artery
N	Aorta bifurcation

X	Tip of IABC
Y	End of IABC
Z	Site of IABC insertion

