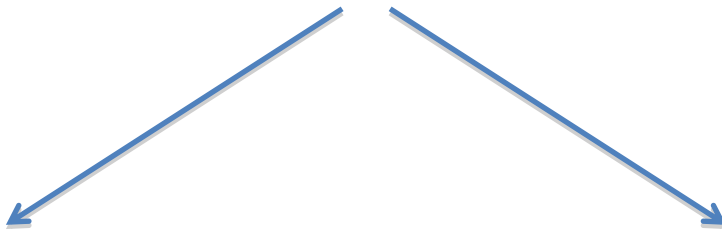


# Gastroduodenal Artery Aneurysm



Accidentally Discovered  
Or  
Non-Ruptured GDA Aneurysm

Ruptured GDA Aneurysm



Hemodynamically

Hemodynamically

Stable


Unstable



Anatomically Feasible  
**for repair**

Endovascular Repair  
(coil embolization, stent placement)

Open Surgery



YES

NO or  
Failed Endovascular **repair**



Endovascular  
Repair

Open Surgery