

Orthoses

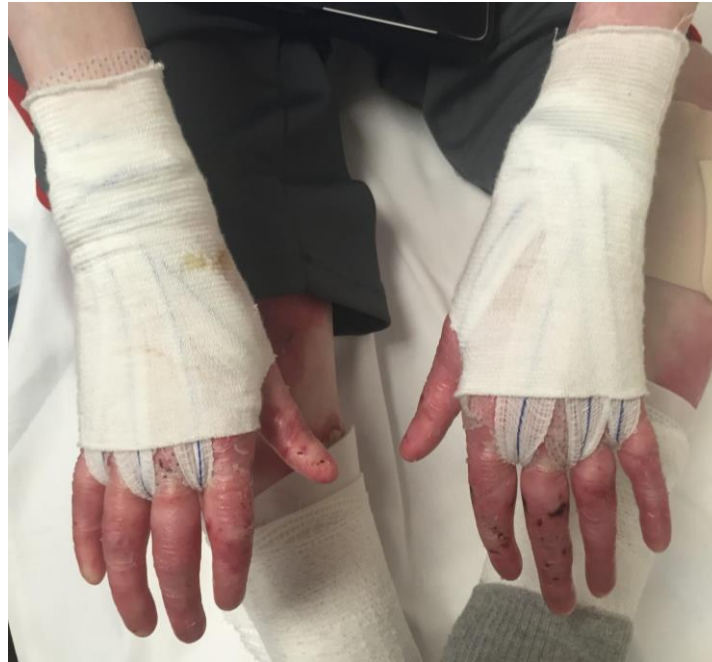

Figure 1: Interdigital finger wrapping

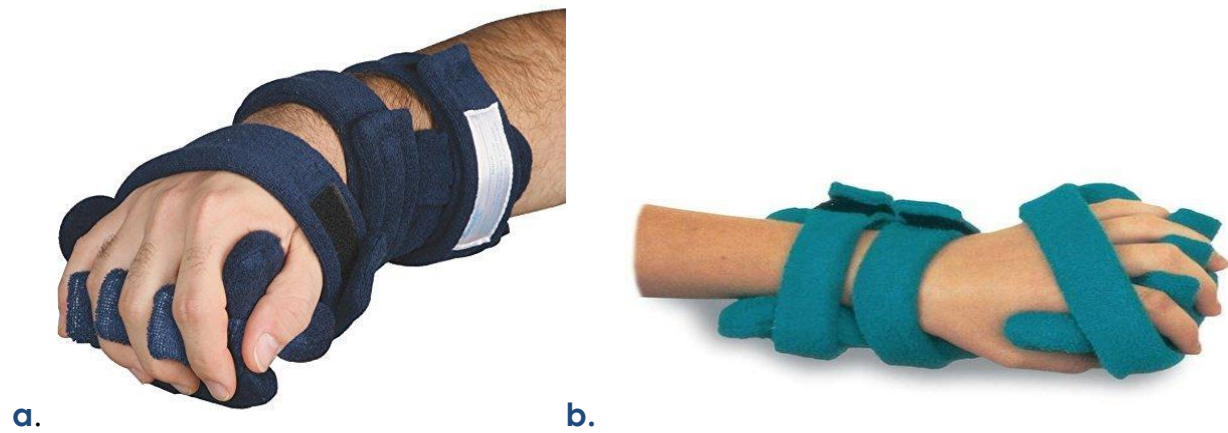

Figure 2: Soft wrist and finger orthosis for **a.** night use **b.** shorter version

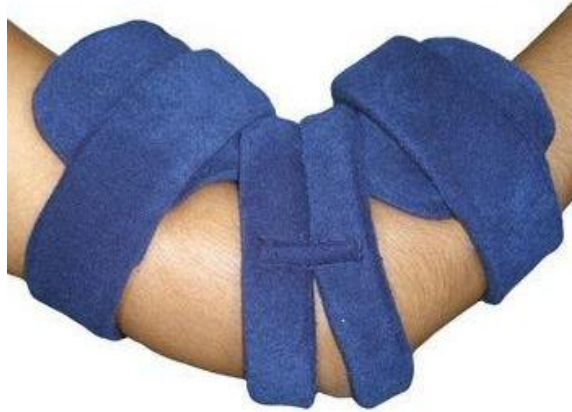

Figure 3: Soft elbow orthosis to maintain elbow extension

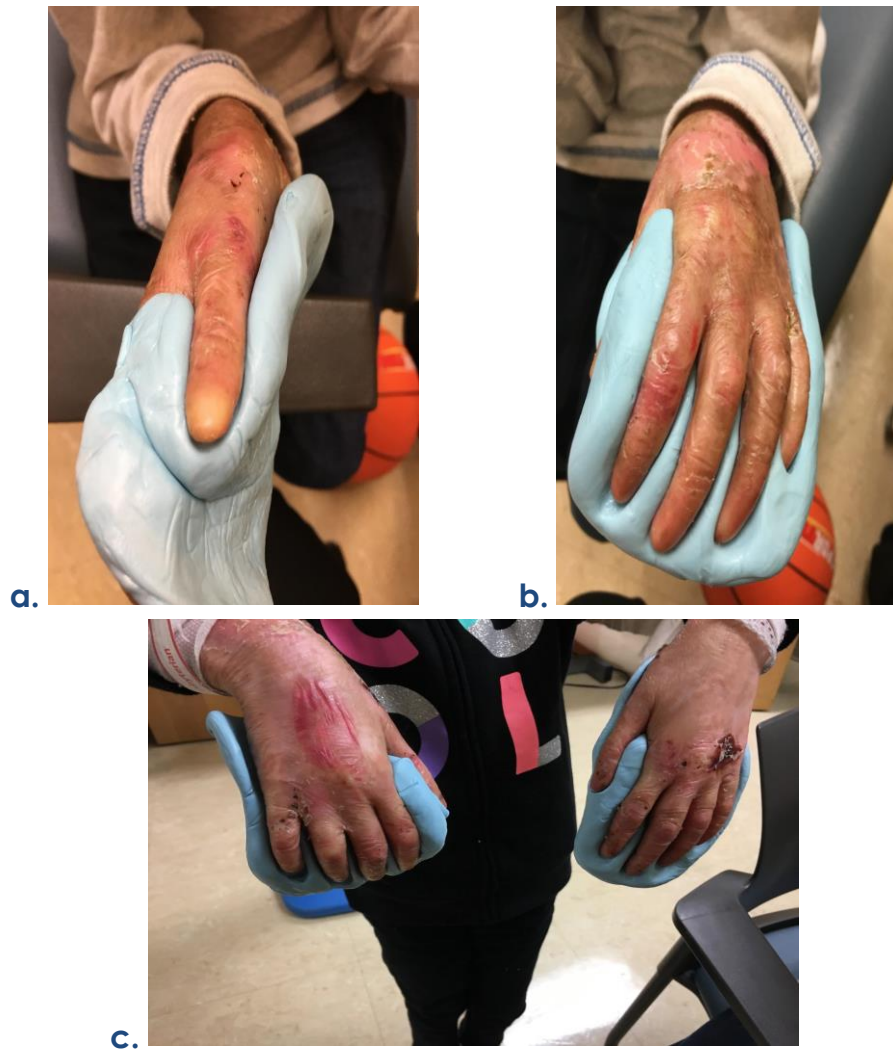


Figure 4: Elastomer (silicone putty) **a.** palmar view; **b.** dorsal view; **c.** to prevent further web creep

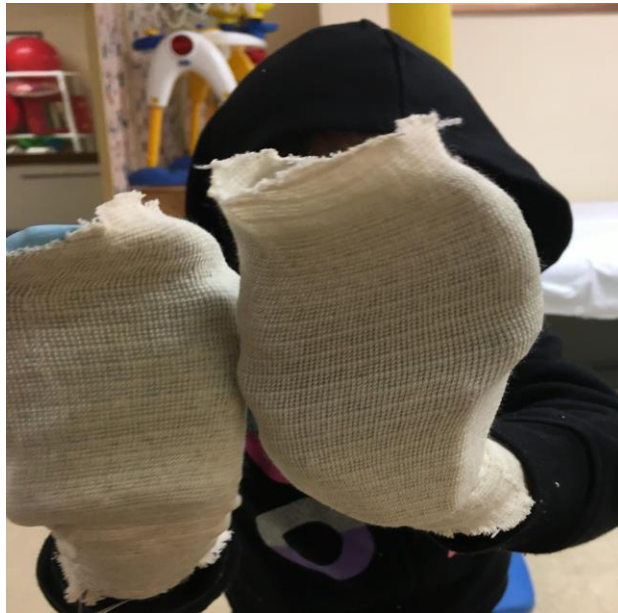

Figure 5: Elastomer orthoses secured with compressive sock material

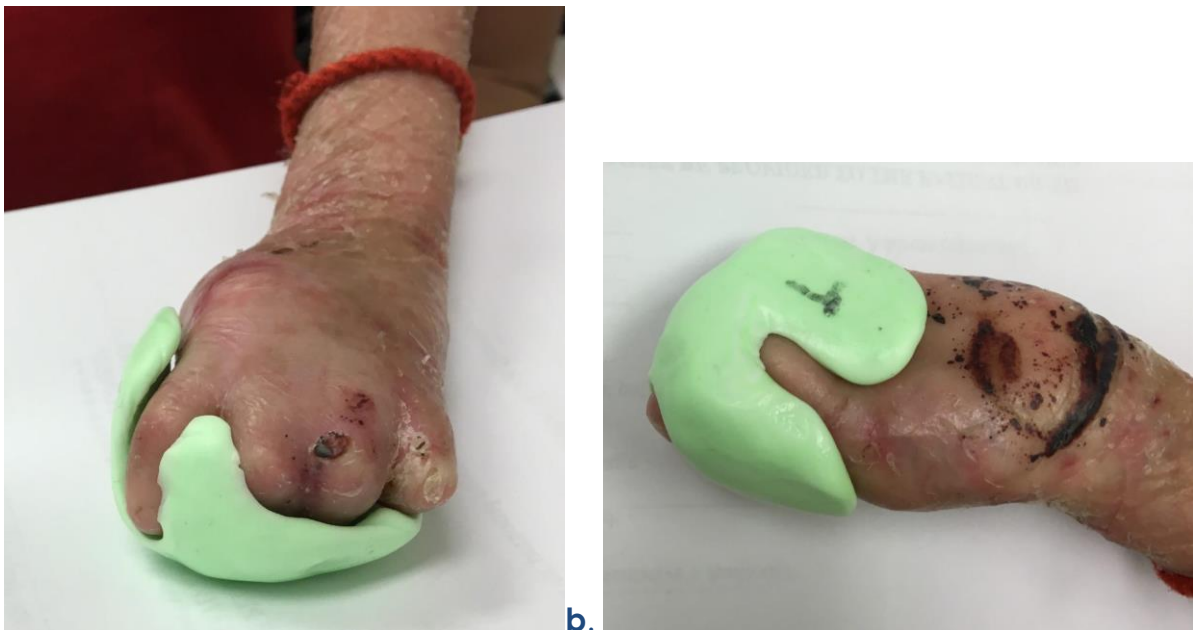

Figure 6: Elastomer used for **a.** maintenance of first web space, dorsal view; **b.** maintenance of first web space, palmar view

For additional examples, resources and suggestions, please refer to Occupational Therapy in Epidermolysis Bullosa by Weiß and Prinz (2013).