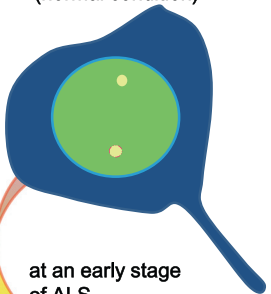


Motor neuron
(normal condition)



at an early stage
of ALS

