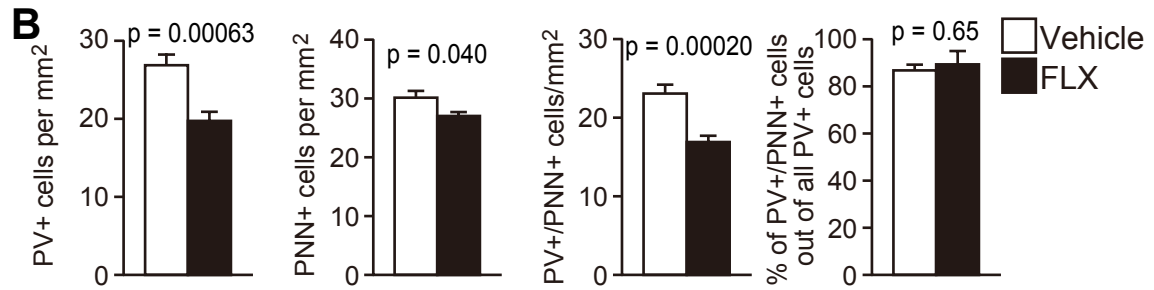
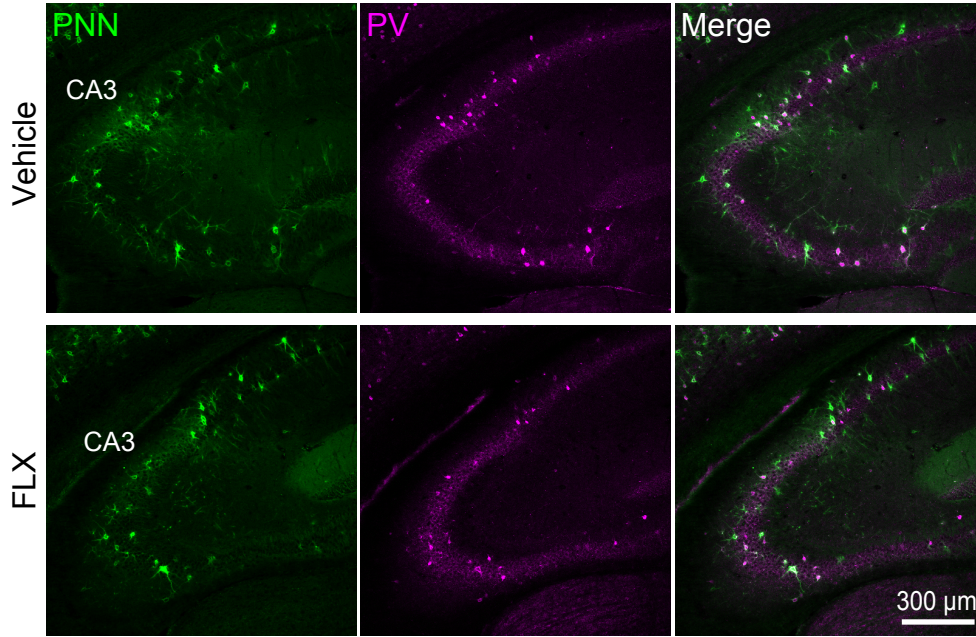


A Hippocampal CA3



C Reticular thalamic nucleus (RTN)

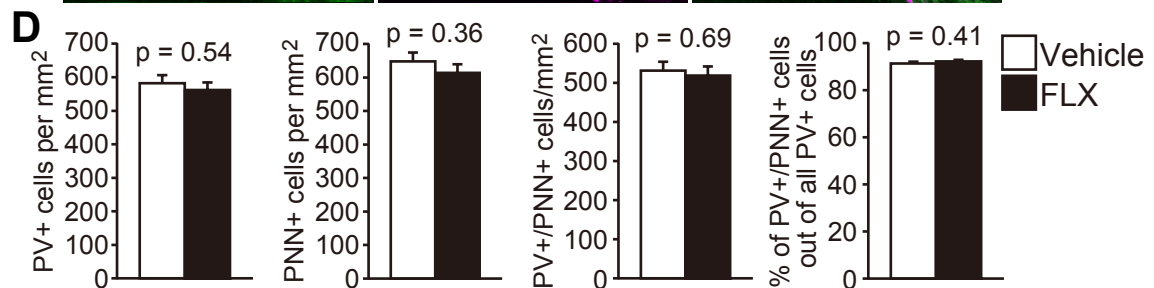
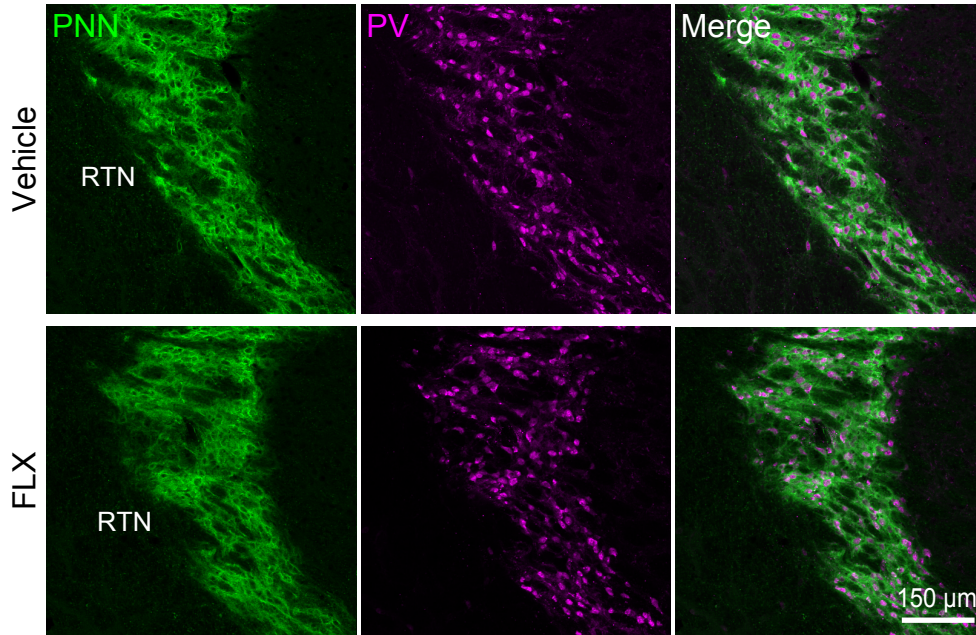


Figure 2