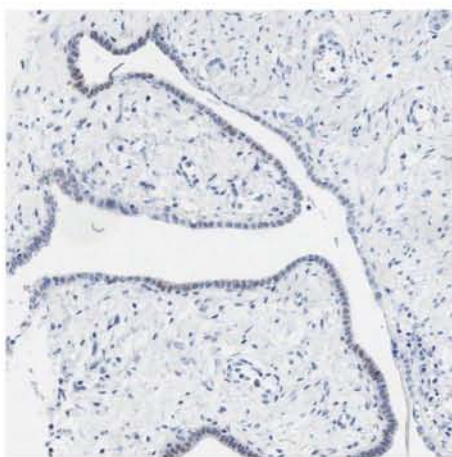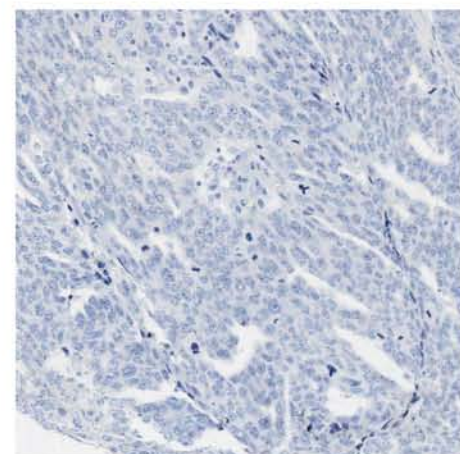
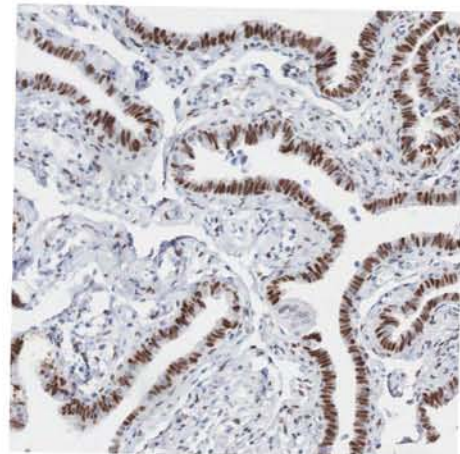
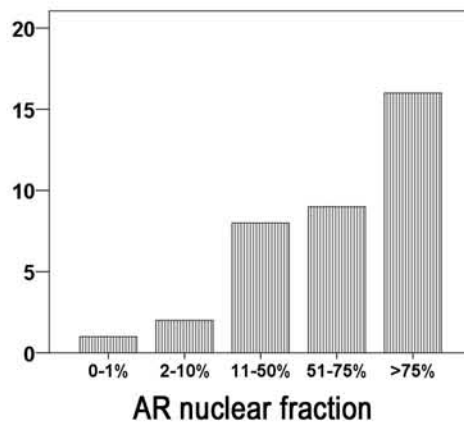
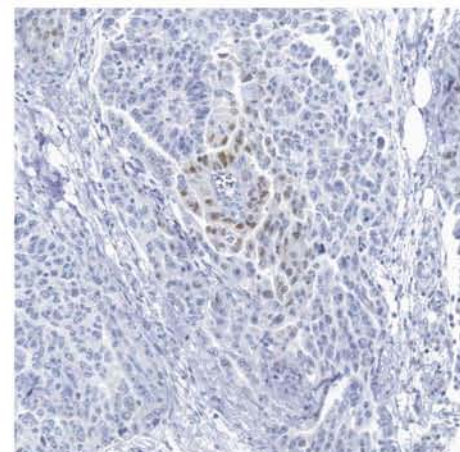
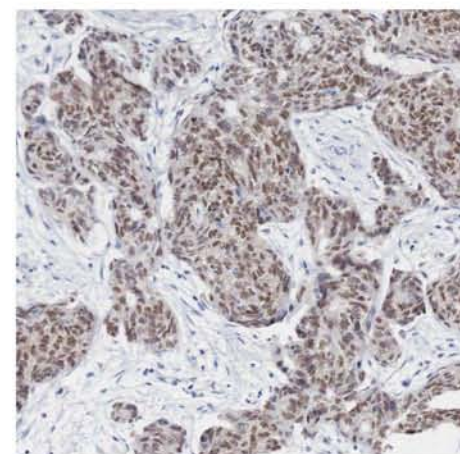
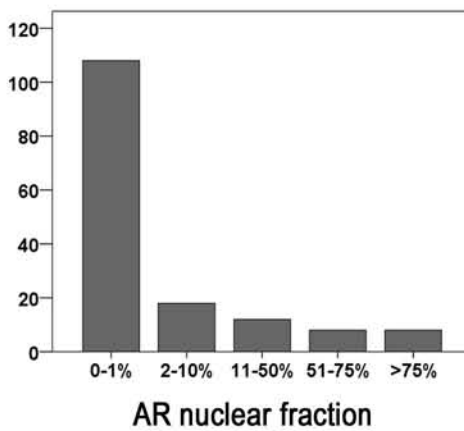


Fallopian tubes



Ovarian cancer



Omental metastases

