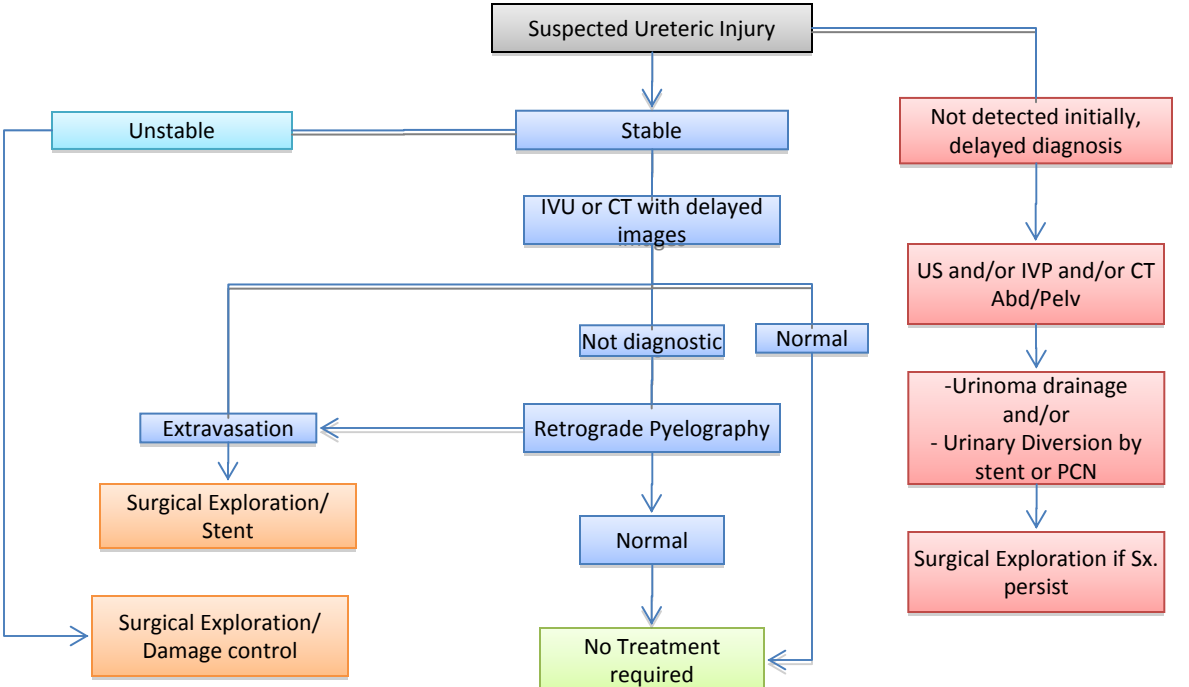
Suspected Ureteric Injury
Unstable
Stable
Not detected initially, delayed diagnosis
IVU or CT with delayed images
US and/or IVP and/or CT Abd/Pelv
Not diagnostic
Normal
-Urinoma drainage and/or
- Urinary Diversion by stent or PCN
Extravasation
Retrograde Pyelography
Surgical Exploration/ Stent
Normal
Surgical Exploration if Sx. persist
Surgical Exploration/ Damage control
No Treatment required