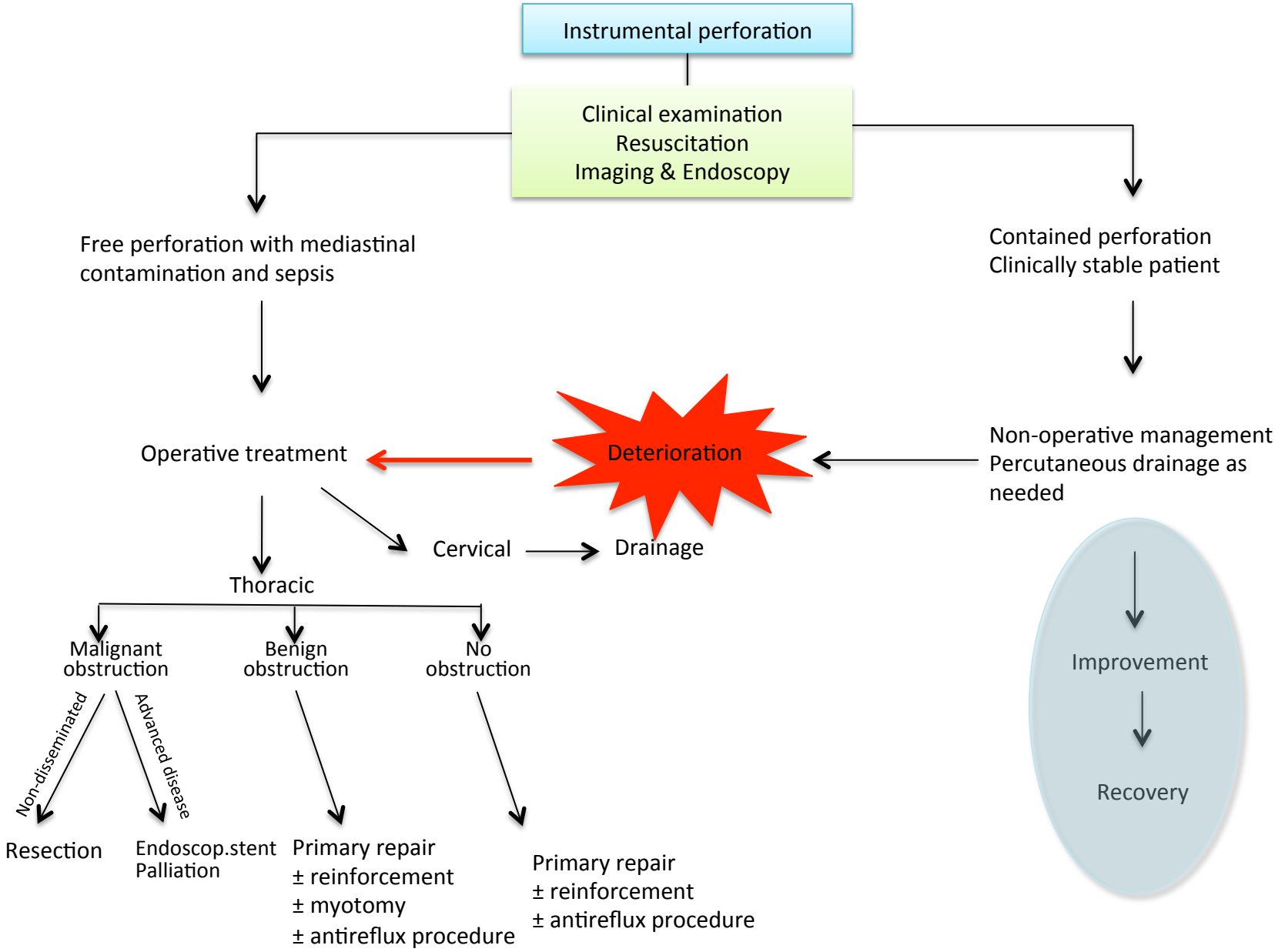
Instrumental perforation
Clinical examination
Resuscitation
Imaging & Endoscopy
Free perforation with mediastinal contamination and sepsis
Contained perforation
Clinically stable patient
Operative treatment
Deterioration
Non-operative management
Percutaneous drainage as needed
Cervical
Drainage
Thoracic
Malignant obstruction
Benign obstruction
No obstruction
Non-disseminated
Advanced disease
Resection
Endoscop.stent
Palliation
Primary repair
± reinforcement
± myotomy
± antireflux procedure
Primary repair
± reinforcement
± antireflux procedure
Improvement
Recovery