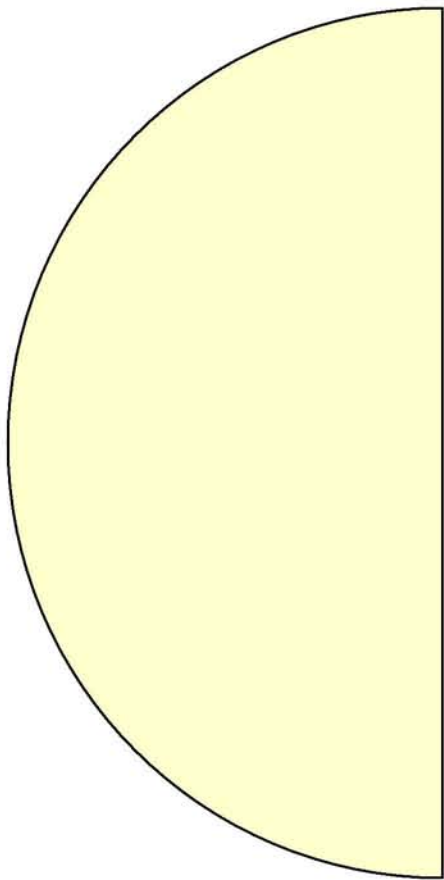
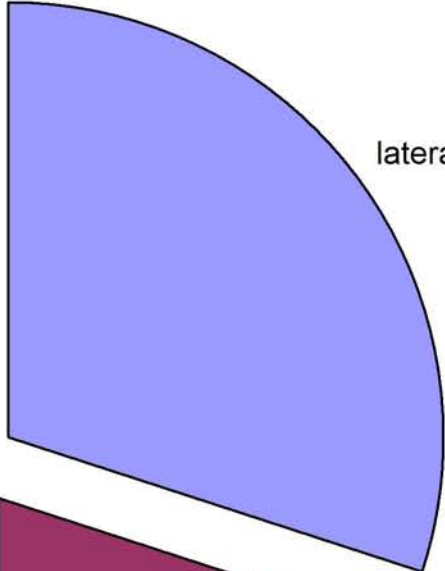


floor of mouth/tongue; 10



lateral mandible; 6



anterior mandible; 4

