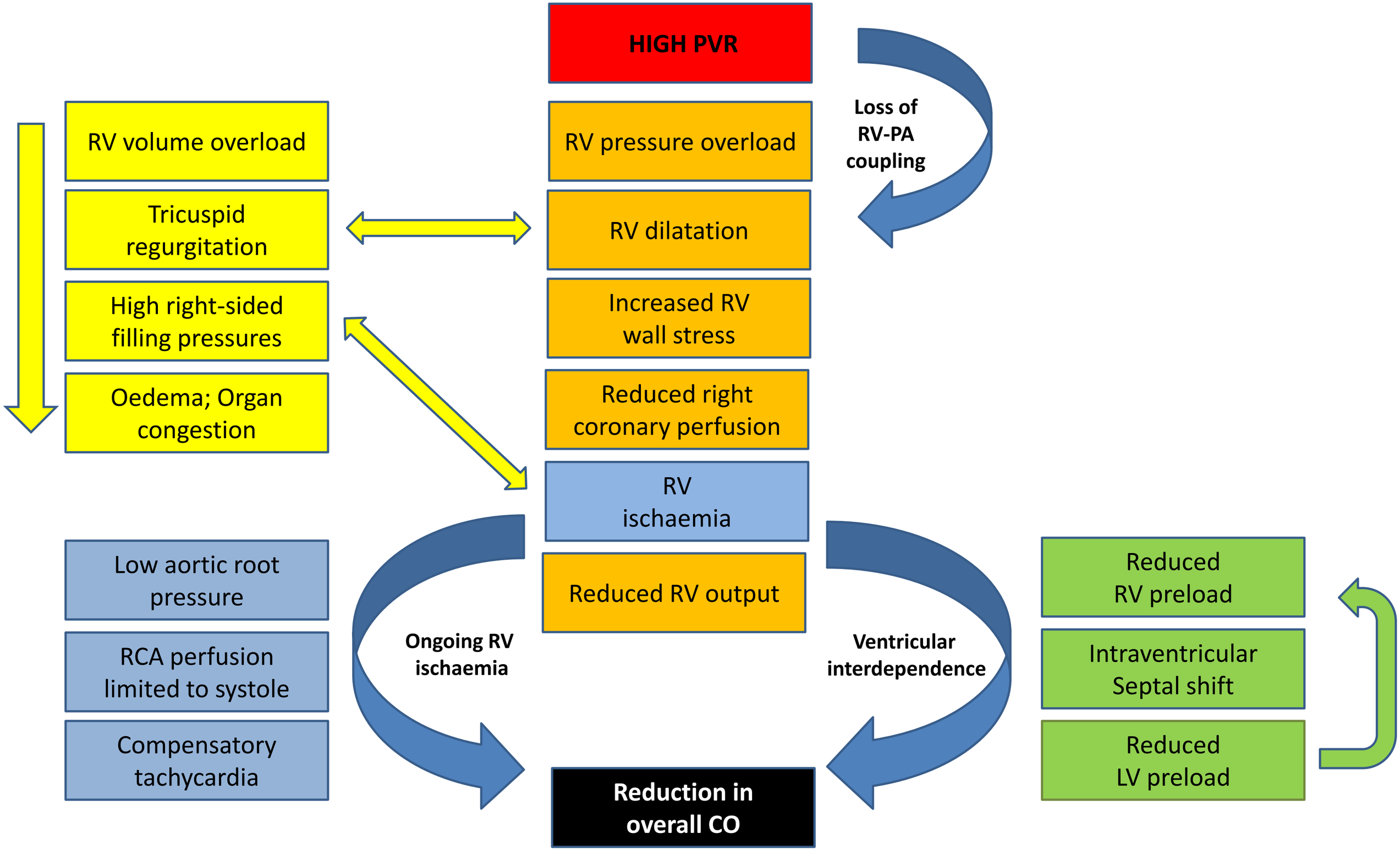
HIGH PVR
Loss of RV-PA coupling
RV volume overload
RV pressure overload
Tricuspid regurgitation
RV dilatation
High right-sided filling pressures
Increased RV wall stress
Oedema; Organ congestion
Reduced right coronary perfusion
RV ischaemia
Low aortic root pressure
Reduced RV output
RCA perfusion limited to systole
Ongoing RV ischaemia
Ventricular interdependence
Compensatory tachycardia
Reduced RV preload
Intraventricular Septal shift
Reduced LV preload
Reduction in overall CO