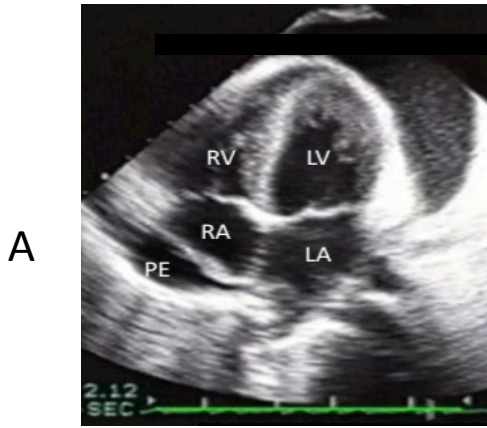
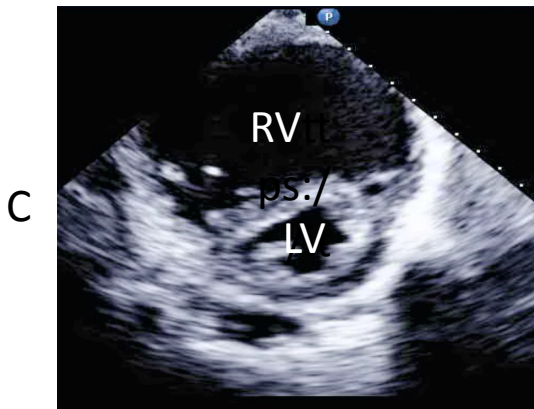
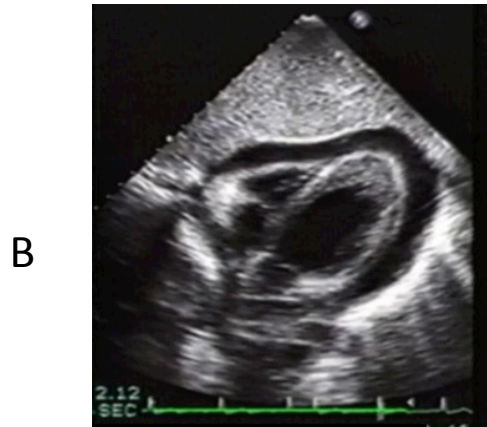


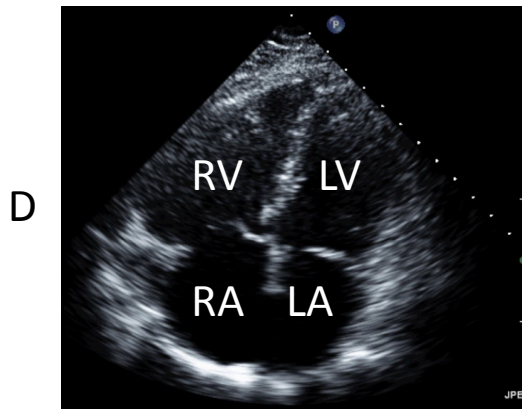
Figure 7



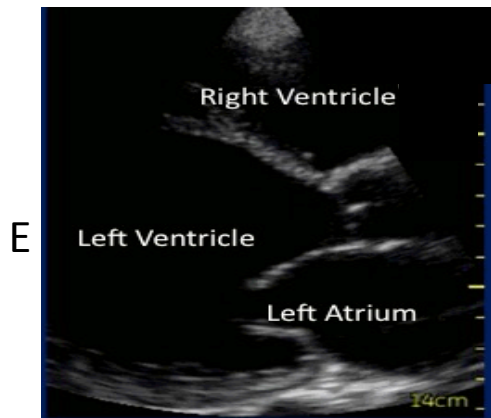
A-4  
Subcostal  
Circumferential Pericardial Effusion



PSAX  
Dilated RV/Septal Flattening



A-4  
Dilated RV/RA



Dilated LV  
PLAX