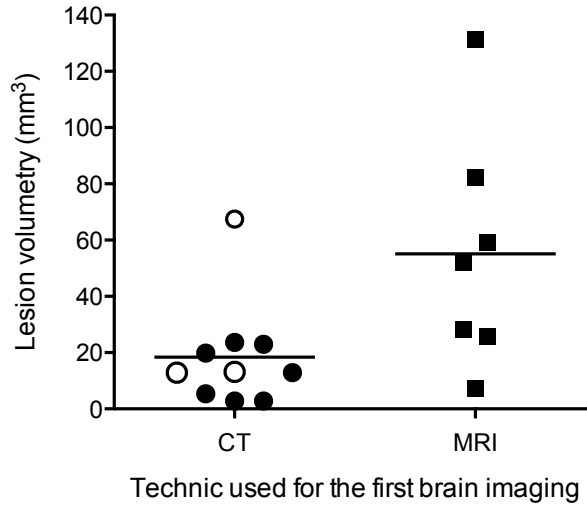
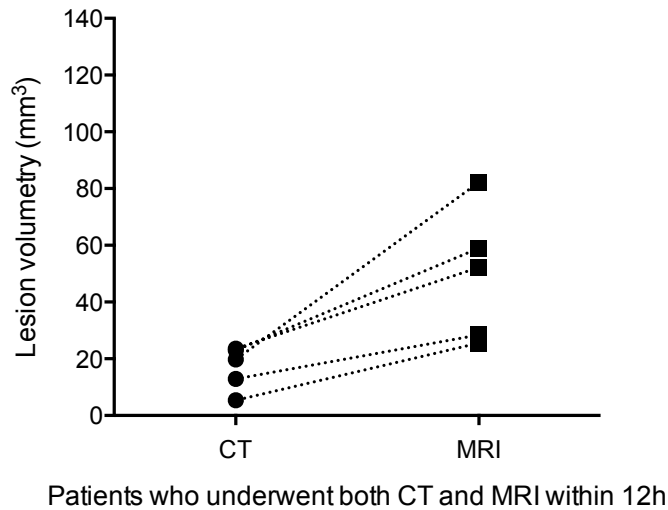


**A****B**

**Additional file 3 - Comparison between brain imaging techniques used for the first brain imaging after admission.** Brain lesion volumetry (mm<sup>3</sup>) measured on the first brain image obtained, depending of the imaging technique used (computed tomography -CT- or magnetic resonance imaging -MRI-), for the entire cohort (**A**), and for paired procedures (**B**). Imaging procedures were considered to be paired if they were performed on the same patient within 12 h of each other. Patients with brain herniation and high intracranial pressure treated by decompressive craniectomy are represented as white dots.